

MINISTRY OF PUBLIC HEALTH OF UKRAINE

Department of human resources policy, education and science

Testing Board

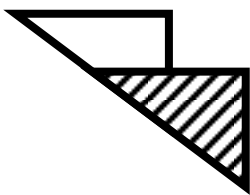
Student ID									

Last name									

Variant _____

Test items for licensing examination

Krok 2 MEDICINE



General Instruction

Every one of these numbered questions or unfinished statements in this chapter corresponds to answers or statements endings. Choose the answer (finished statements) that fits best and fill in the circle with the corresponding Latin letter on the answer sheet.

Authors of items: Abaturov O.Ye., Agarkov V.I., Alexeyenko L.I., Andrusha A.B., Artamonov V.S., Badogina L.P., Barannyk S.I., Belyakova V.I., Berezov V.M., Bezborod'ko S.A., Bilous T.M., Blikhar V.Ye., Bondarenko V.V., Borovkova S.O., Borysova T.P., Borzova O.Yu., Bukhteyeva E.R., Burka O.A., Buryak V.M., Butvyn I.M., Chonka I.I., Demchenko T.V., Derkach V.G., Detsyk O.Z., Dobrovols'ka L.M., Dzis' N.P., Dzyuba G.A., Emiraliyeva Z.R., Franchuk O.A., Galushchenko S.A., Gendeleka G.F., Genyk N.I., Gerasymenko O.I., Goryachev V.V., Grebenyuk V.I., Grydasova V.D., Gurenko O.G., Gusak O.M., Ivanits'ka O.V., Ivanyuta S.O., Kaporina N.V., Karliychuk O.O., Khymenko M.F., Kol'tsova N.I., Kolyadenko N.V., Kondratenko P.G., Konopkina L.I., Koval'ova O.M., Kovtun A.I., Kovtunenکو R.V., Kravchenko O.V., Krut' Yu.Ya., Krylova V.Yu., Kryvonosov M.V., Kubyschyn V.F., Kudiyevsky A.V., Kudrevych O.M., Kudrya V.I., Kuz'menko A.Ya., Kuz'menko S.A., Kvasnyts'ka O.B., Latypova G.A., Lishchenko N.O., Lysenko D.A., Lysenko V.M., Marichereda V.G., Martynik Ye.M., Martynyuk L.P., Maruschko Yu.V., Mel'nychuk L.V., Mischchenko V.P., Moroz I.M., Myerkulova N.F., Mysak A.I., Nikitina N.O., Nitsovykh R.M., Nishkumay O.I., Ogniyev V.A., Okhrimenko G.I., Oliynyk O.Ye., Ostropolets' M.S., Pavlovykh L.V., Perepelyuk M.M., Perminova T.I., Pisots'ka L.A., Prokhoda A.F., Prokopchuk G.L., Prokopova L.V., Proniv L.M., Prunchak I.F., Prus L.O., Reva V.B., Romanenko V.N., Roshchupkina S.L., Rudenko M.M., Rudenko O.F., Ryapolova T.L., Rybalka A.M., Syabadash V.Ye., Sakevykh P.P., Sannikova N.M., Selez'n'ova S.V., Sels'ka O.V., Semenukha K.V., Semenyak A.V., Shcherbatyuk N.Yu., Shevchenko O.A., Shevchenko R.S., Shumko G.I., Shusterman T.Y., Sipityi V.I., Sichanova O.V., Slyepichko Yu.M., Slyva V.I., Smirnova V.L., Soldak I.I., Spirina I.D., Stepanyuk L.I., Sterniyuk Yu.M., Svidro O.V., Svyrydova V.V., Syerkova V.K., Synovers'ka O.B., Sychova V.V., Tarallo V.L., Titarenko O.V., Tkachenko M.M., Tkachuk O.L., Tomash O.V., Tsyunchyk Yu.G., Tyuyeva N.V., Urbas' O.V., Uryvayeva M.K., Usychenko O.M., Vankhanen N.V., Vankhanen V.D., Varbanets' D.A., Vasil'yeva N.V., Vasil'chyshyn Ya.V., Velyka N.V., Vereschagina N.Ya., Vinentsov Yu.O., Volyans'ka A.G., Vorkhlyk M.I., Vorokhta Yu.M., Yermachenko T.P., Yevdokimova T.B., Yevtushenko V.V., Yakovenko I.K., Yakubyshyna I.G., Yamilova T.M., Yudina T.V., Yurchenko I.V., Yurlov V.M., Yutanova A.V., Zakharchenko Yu.B., Zakharov V.K., Zavizion V.F., Zazdravnov A.A., Zelyak M.V., Zheliba M.D., Zhuravel V.I., Zhurilo I.P., Znakhurenko L.S., Zorya A.V., Zuban' A.B. and Committees of professional expertise.

Item reviewers. Agafonova O.O., Anisimov Ye.M., Bab'yak T.Ye., Chursina T.Ya., Dyndar O.A., Grygorov Yu.B., Grynzovs'ky A.M., Gubka V.O., Gutsalenko O.O., Kalinina S.Yu., Karapetyan K.G., Khrapach V.V., Kolesnyk O.M., Kolosovych I.V., Kondratyuk V.Ye., Kopcha V.S., Kravchenko O.V., Kutovy O.B., Kuz'mina I.Yu., Malanchuk L.M., Martynyuk L.P., Mishchenko V.P., Muravs'ka O.M., Petrushenko V.V., Prokhorova M.P., Pryshlyak O.Ya., Puzanova O.G., Pyptyuk O.V., Shestakova I.V., Shevtsova T.I., Stovban I.V., Tsvirenko S.M., Usenko S.G., Vakal'uk I.P., Volyans'ka A.G.

The book includes test items for use at licensing integrated examination "Krok 2. Medicine" and further use in teaching.

The book has been developed for students of medical, pediatric and medical-and-prophylactic faculties and academic staff of higher medical educational establishments.

Approved by Ministry of Public Health of Ukraine as examination and teaching publication based on expert conclusions (Orders of MPH of Ukraine of 14.08.1998 №251, of 27.12.1999 №303, of 16.10.2002 №374, of 29.05.2003 №233).

1. 13 months after the first labor a 24-year-old patient complained of amenorrhea. Pregnancy ended in Caesarian section because of premature detachment of normally positioned placenta which resulted in blood loss at the rate of 2000 ml due to disturbance of blood clotting. Choose the most suitable investigation:

- A. Estimation of gonadotropin rate
- B. US of small pelvis
- C. Progesteron assay
- D. Computer tomography of head
- E. Estimation of testosterone rate in blood serum

2. A 24-year-old primipara was hospitalised with complaints of discharge of the amniotic waters. The uterus is tonic on palpation. The position of the fetus is longitudinal, it is pressed with the head to pelvic outlet. Palpitation of the fetus is rhythmical, 140 bpm, auscultated on the left below the navel. Internal examination: cervix of the uterus is 2,5 cm long, dense, the external opening is closed, light amniotic waters are discharged. Point out the correct component of the diagnosis:

- A. Antenatal discharge of the amniotic waters
- B. Early discharge of the amniotic waters
- C. The beginning of the 1st stage of labour
- D. The end of the 1st stage of labour
- E. Pathological preterm labour

3. A patient was delivered to a surgical department after a road accident with a closed trauma of chest and right-sided rib fracture. The patient was diagnosed with right-sided pneumothorax; it is indicated to perform drainage of pleural cavity. Pleural puncture should be made:

- A. In the 2nd intercostal space along the middle clavicular line
- B. In the 6th intercostal space along the posterior axillary line
- C. In the 7th intercostal space along the scapular line
- D. In the projection of pleural sinus
- E. In the point of the greatest dullness on percussion

4. A primagravida with pregnancy of 37-38 weeks complains of headache, nausea, pain in epigastrium. Objectively: the skin is acyanotic. Face is hydropic, there is short fibrillar twitching of blepharons, muscles of the face and the inferior extremities. The stare is fixed. BP - 200/110 mm Hg; sphygmus is of 92 bpm, intense. Respiration rate is 32/min. Heart activity is rhythmical. Appreciable edemas of the inferior extremities are present. Urine is cloudy. What medication should be administered?

- A. Droperidolum of 0,25% - 2,0 ml
- B. Dibazolium (Bendazole hydrochloride) of 1% - 6,0 ml
- C. Papaverine hydrochloride of 2% - 4,0 ml
- D. Hexenalum of 1% - 2,0 ml
- E. Pentaminum of 5% - 4,0 ml

5. A patient with high temperature came to a first-aid post in the evening. The fact of temporary disability was established. Indicate the measure to be taken in this case:

- A. The night duty doctor should issue a medical certificate, which will be subsequently used for issuing a sick list from the date of the previous day
- B. The sick list for 1 day should be issued
- C. The sick list for up to 3 days should be issued
- D. The sick list for 3 days should be issued
- E. No document should be issued

6. A 10-year-old boy complains of pain in his left eye and strong photophobia after he has injured his left eye with a pencil at school. Left eye examination revealed: blepharospasm, ciliary and conjunctival congestion, cornea is transparent, other parts of eyeball have no changes. Visus 0,9. Right eye is healthy, Visus 1,0. What additional method would you choose first of all?

- A. Staining test with 1% fluorescein
- B. X-ray examination of orbit
- C. Tonometria
- D. Gonioscopia
- E. Cornea sensation-test

7. An infant was born with body mass 3 kg and body length 50 cm. Now he is 3 years old. His brother is 7 years old, suffers from rheumatic fever. Mother asked a doctor for a cardiac check up of the 3-year-old son. Where is the left relative heart border located?

- A. 1 cm left from the left medioclavicular line
- B. 1 cm right from the left medioclavicular line
- C. Along the left medioclavicular line
- D. 1 cm left from the left parasternal line
- E. 1 cm right from the left parasternal line

8. A baby was born at 36 weeks of gestation. Delivery was normal, by natural way. The baby has a large cephalohematoma. The results of blood count are: Hb- 120g/l, Er- $3,5 \cdot 10^{12}/l$, total serum bilirubin - 123 mmol/l, direct bilirubin - 11 mmol/l, indirect - 112 mmol/l. What are the causes of hyperbilirubinemia in this case?

- A. Erythrocyte hemolysis
- B. Intravascular hemolysis
- C. Disturbance of the conjugative function of liver
- D. Bile condensing
- E. Mechanical obstruction of the bile outflow

9. A patient has been hospitalised. The onset of the disease was gradual: nausea, vomiting, dark urine, acholic stool, yellowness of the skin and scleras. The liver is enlarged by 3 cm. Jaundice

developed on the 14th day of the disease. The liver diminished in size. What complication of viral hepatitis caused deterioration of the patient's condition?

- A. Hepatic encephalopathy
- B. Meningitis
- C. Relapse of viral hepatitis
- D. Cholangitis
- E. Infectious-toxic shock

10. An 18-year-old patient was admitted to a hospital with complaints of headache, weakness, high fever, sore throat. Objectively: enlargement of all groups of lymph nodes was revealed. The liver is enlarged by 3 cm, spleen - by 1 cm. In blood: leukocytosis, atypical lymphocytes - 15%. What is the most probable diagnosis?

- A. Infectious mononucleosis
- B. Acute lymphoid leukosis
- C. Diphtheria
- D. Angina
- E. Adenoviral infection

11. A 60-year-old woman, mother of 6 children, developed a sudden onset of upper abdominal pain radiating to the back, accompanied by nausea, vomiting, fever and chills. Subsequently, she noticed yellow discoloration of her sclera and skin. On physical examination the patient was found to be febrile with temperature of 38,9°C, along with right upper quadrant tenderness. The most likely diagnosis is:

- A. Choledocholithiasis
- B. Benign biliary stricture
- C. Malignant biliary stricture
- D. Carcinoma of the head of the pancreas
- E. Choledochal cyst

12. What juice is recommended to be included in a complex drug and diet therapy for patients suffering from gastric or duodenal ulcer and high acidity of gastric juice to speed up ulcer healing?

- A. Potato, potato-carrot
- B. Apple, apple-birch
- C. Pumpkin
- D. Cabbage, cabbage-carrot
- E. Celery, parsley

13. A 40-year-old woman has been hospitalized for attacks of asphyxia, cough with phlegm. She has a 4-year history of the disease. The first attack of asphyxia occurred during her stay in the countryside. Further attacks occurred while cleaning the room. After 3 days of inpatient treatment the patient's condition has significantly improved. What is the most likely etiological factor?

- A. Household allergens
- B. Pollen
- C. Infectious
- D. Chemicals
- E. Psychogenic

14. A 13-year-old girl complains of periodic prickly pain in the heart region. Percussion revealed no changes of cardiac borders. Auscultation revealed arrhythmic enhanced heart sounds, extrasystole at the 20-25 cardiac impulse. ECG showed the sinus rhythm, impaired repolarization, single supraventricular extrasystoles at rest. What is the most likely diagnosis?

- A. Somatoform autonomic dysfunction
- B. Rheumatism
- C. Nonrheumatic carditis
- D. Myocardial degeneration
- E. Intoxication syndrome

15. A 24-year-old patient visited a doctor complaining of enlargement of his submaxillary lymph nodes. Objectively: submaxillary, axillary and inguinal lymph nodes are enlarged. Chest X-ray shows: enlarged lymph nodes of mediastinum. Blood test: erythrocytes - $3,4 \cdot 10^{12}/l$, Hb- 100 g/l, blood colour index - 0,88, platelets - $190 \cdot 10^9/l$, leucocytes - $7,5 \cdot 10^9/l$, eosinophiles - 8%, band neutrophiles - 2%, segmented neutrophiles - 67%, lymphocytes - 23%, ESR - 22 mm/h. What test must be prescribed to verify the cause of lymphadenopathy?

- A. Open biopsy of lymph nodes
- B. Ultrasonography of abdominal cavity
- C. Mediastinum tomography
- D. Puncture biopsy of lymph nodes
- E. Sternal puncture

16. A 60-year-old woman has been suffering from arterial hypertension for 15 years. After recurrent stroke she started complaining about unmotivated bad mood, problems with attention concentration; she forgets to close the entrance door, cannot recall events of the past day. Computer tomography shows areas of postinfarction changes in the cortical postfrontal areas. What is the most probable diagnosis?

- A. Vascular dementia
- B. Alzheimer's disease
- C. Huntington's disease
- D. Pick's disease
- E. Dissociative amnesia

17. Clinic of a research institute for occupational diseases examined a worker who works at a concentration plant and diagnosed him with chronic dust bronchitis. The case is investigated by a commission including the representatives of: the plant, medical unit, territorial sanitation center, department of Social Insurance Fund, trade union. According to the "regulation on investigation of...", the commission should be headed by the representative of the following authority:

- A. Territorial sanitation center
- B. Plant
- C. Social Insurance Fund
- D. Trade union
- E. Medical unit

18. 4 days after a patient received a gunshot wound of the middle third of the thigh soft tissues his condition suddenly began deteriorating. There are complaints of bursting pain in the wound; pain increases during the last 12 hours. Edema of skin and hypodermic tissue quickly grows. Body temperature is $38,2^{\circ}\text{C}$, heart rate is 102/min. The wound edges gape, are dull in color; the muscles, viable as of day before, now protrude into the wound, look boiled, are dull in colour, have dirty-grey coating and fall apart when being held with forceps. What infection has developed in the wound?

- A. Anaerobic
- B. Aerobic gram-negative
- C. Putrid
- D. Aerobic gram-positive
- E. Diphtheria of wound

19. Bacterial analysis of air in a living space in winter period by means of Krotov's apparatus revealed that total number of microorganisms in 1m^3 of air was 7200. What is the allowed number of microorganisms for the air to be characterized as "pure"?

- A. Up to 4500
- B. Up to 2500
- C. Up to 3500
- D. Up to 5500
- E. Up to 7500

20. Maximum permissible concentration of carbon dioxide in the air is considered to be a sanitary index of air purity in a classroom. What concentration of carbon dioxide in the air is accepted as a permissible maximum?

- A. 0,1%
- B. 0,05%
- C. 0,15%
- D. 0,2%
- E. 0,3%

21. When examining the parameters of desk natural lighting in a school class it was determined that: light angle is 25° , window angle is 3° , window-to-floor area ratio is 1:4, daylight factor is 0,5%, and window-head-to-room-depth ratio is 2. What parameter does not correspond to hygienic norms?

- A. Daylight factor
- B. Window angle
- C. Window-to-floor area ratio
- D. Window-head-to-room-depth ratio
- E. Light angle

22. A 29-year-old patient works as a motor mechanic. Anamnesis shows frequent exposure to cold, exacerbation of chronic bronchitis attended by cough with relatively small amount of mucopurulent sputum, subfebrility, someti-

mes joined by hemoptysis and pain in the right side of chest. Breathing is vesicular. X-ray shows darkening and sharp decrease in size of the lower lobe distinctly visible on the X-ray image as a streak 2-3 cm wide situated at the angle from lung root to the frontal costodiaphragmatic recess. The most likely diagnosis is:

- A. Peripheral lung cancer
- B. Bronchiectasis
- C. Pneumonia
- D. Middle lobe syndrome
- E. Interlobular pleurisy

23. A 52-year-old patient, who has been suffering from angina pectoris for 2 weeks, has more and more frequent pain attacks in the area behind his sternum and his need for nitroglycerine increased. Objectively: the condition is of moderate severity. Skin is pale. Heart sounds are weakened, rhythmic. Heart rate is 84 per minute. ECG shows no signs of focal myocardial damage. What is the most likely diagnosis?

- A. Progressive angina pectoris
- B. First-time angina pectoris
- C. Stable FC II angina pectoris
- D. Variant angina pectoris
- E. Acute cardiac infarction

24. An 8-year-old boy during preventive examination was determined to have changes in his spine curvature in frontal plane: the right shoulder is lowered and flat, scapulae angles are of different height due to the right scapula being shifted down. Waist triangles are pronounced on the both sides; longitudinal muscles of the back form muscle cushion on the left. What type of posture is detected in the child?

- A. Scoliotic
- B. Kyphotic
- C. Lordotic
- D. Stooping
- E. Corrected

25. A patient with cardiac infarction is on sick leave with his medical certificate being continuously extended for 4 months according to a standard procedure. The disease is progressing. The issue is put forward to refer the patient to the industrial injury assessment board. Who among the medical staff of medical and preventive treatment facility is authorized to do this?

- A. Medical expert committee
- B. Attending medical doctor
- C. Head doctor of hospital department
- D. Deputy head doctor for assessment of temporary disability
- E. Head doctor

26. A 9-year-old boy has been suffering from bronchoectasis since he was 3. Exacerbations occur quite often, 3-4 times a year. Conservative therapy results in short periods of remi-

ssion. The disease is progressing, the child has physical retardation. The child's skin is pale, acrocyanotic, he has "watch glass" nail deformation. Bronchography revealed saccular bronchiectases of the lower lobe of his right lung. What is the further treatment tactics?

- A. Surgical treatment
- B. Further conservative therapy
- C. Physiotherapeutic treatment
- D. Sanatorium-and-spa treatment
- E. Tempering of the child's organism

27. A 29-year-old female patient complains of dyspnea, heaviness and chest pain on the right, body temperature rise up to $37,2^{\circ}\text{C}$. The disease is associated with a chest trauma received 4 days ago. Objectively: skin is pale and moist. Heart rate is 90 bpm, regular. Palpation reveals a dull sound on the right, auscultation reveals significantly weakened vesicular breathing. In blood: RBCs - $2,8 \cdot 10^{12}/\text{l}$, colour index - 0,9, Hb- 100 g/l, WBCs - $8,0 \cdot 10^9/\text{l}$, ESR - 17 mm/h. What results of diagnostic puncture of the pleural cavity can be expected?

- A. Haemorrhagic punctate
- B. Chylous liquid
- C. Exudate
- D. Transudate
- E. Purulent punctate

28. A 54-year-old man had been drowning at sea, when he was found and evacuated to the shore. Objectively: unconscious, pale face, no breathing can be auscultated, thready pulse. Resuscitation measures allowed to save the man. What complication can develop in him in the nearest future?

- A. Pulmonary edema
- B. Respiratory arrest
- C. Encephalopathy
- D. Cardiac arrest
- E. Bronchial spasm

29. A 7-year-old child complains of cramping pain occurring after mental exertion, cold drinks and eating ice-cream. Instrumental examination allowed to diagnose biliary dyskinesia of hypertensive type. What group of drugs should be prescribed for treatment?

- A. Antispasmodics and cholagogues
- B. Cholagogues and choleretics
- C. Sedatives and choleretics
- D. Antioxydants
- E. Antibiotics

30. Caries morbidity rate is 89% among residents of a community. It is determined that fluorine content in water is 0,1 mg/l. What preventive measures should be taken?

- A. Water fluorination
- B. Tooth brushing
- C. Fluorine inhalations
- D. Sealant application
- E. Introduce more vegetables to the diet

31. A 46-year-old patient once took part in elimination of breakdown at an atomic power plant. Currently he is being treated at an inpatient hospital unit. He was diagnosed with progressing somatoform autonomic dysfunction. This disease relates to the following group of ionizing radiation effects:

- A. Somato-stochastic
- B. Somatic
- C. Genetic
- D. Hormesis
- E. Heterosis

32. A patient complains of fatigue, lack of appetite, pain and burning sensation in the tongue, numbness of the distal limbs, diarrhea. Objectively: pale skin with lemon-yellow tint, face puffiness, brown pigmentation in the form of a "butterfly", bright red areas on the tongue. The liver is 3 cm below the costal margin, soft. Blood count: RBCs - $1,5 \cdot 10^{12}/\text{l}$, colour index - 1,2, WBCs - $3,8 \cdot 10^9/\text{l}$, thrombocytes - $180 \cdot 10^9/\text{l}$, eosinophiles - 0%, stab neutrophils - 1%, segmented neutrophils - 58%, lymphocytes - 38% monocytes - 3%, RBC macrocytosis. ESR - 28 mm/h. What diagnosis are these presentations typical for?

- A. B_{12} -deficiency anemia
- B. Iron deficiency anemia
- C. Aplastic anemia
- D. Acute erythromyelosis
- E. Chronic adrenal failure

33. A 25-year-old female patient complains of marked weakness, sleepiness, blackouts, dizziness, taste disorder. The patient has a history of menorrhagia. Objectively: the patient has marked weakness, pale skin, cracks in the corners of her mouth, peeling nails, systolic apical murmur. Blood test results: RBC - $3,4 \cdot 10^{12}/\text{l}$, Hb- 70 g/l, colour index - 0,75, platelets - $140 \cdot 10^9/\text{l}$, WBC- $6,2 \cdot 10^9/\text{l}$. What is the most likely diagnosis?

- A. Chronic posthemorrhagic anemia
- B. Acute leukemia
- C. Acute posthemorrhagic anemia
- D. B_{12} -deficiency anemia
- E. Werlhof's disease

34. A 39-year-old patient complains of morning headache, appetite loss, nausea, morning vomiting, periodic nasal haemorrhages. The patient had acute glomerulonephritis at the age of 15. Examination revealed rise of arterial pressure up to 220/130 mm Hg, skin haemorrhages on his arms and legs, pallor of skin and mucous membranes. What biochemical parameter is the most important for making diagnosis in this case?

- A. Blood creatinine
- B. Blood bilirubin
- C. Blood sodium
- D. Uric acid
- E. Fibrinogen

35. A child was taken to a hospital with focal changes in the skin folds. The child was anxious during examination, examination revealed dry skin with solitary papulous elements and ill-defined lichenification zones. Skin eruption was accompanied by strong itch. The child usually feels better in summer, his condition is getting worse in winter. The child has been on bottle feeding since he was 2 months old. He has a history of exudative diathesis. His grandmother on his mother's side has bronchial asthma. What is the most likely diagnosis?

- A.** Atopic dermatitis
- B.** Contact dermatitis
- C.** Seborrheal eczema
- D.** Strophulus
- E.** Urticaria

36. An electro-gas welding operator working at a machine workshop performs welding and cutting of metal, which is accompanied by intense UV-radiation. His welding station is equipped with effective mechanical ventilation. What occupational disease is most likely to develop in the electro-gas welding operator?

- A.** Photoelectric ophthalmia
- B.** Heatstroke
- C.** Vegetative-vascular dystonia
- D.** Chronic overheating
- E.** Pneumoconiosis

37. 2 weeks after recovering from tonsillitis an 8-year-old boy developed edemas of face and lower limbs. Objectively: the patient is in grave condition, BP - 120/80 mm Hg. Urine is of dark brown colour. Oliguria is present. On urine analysis: specific gravity - 1,015, protein - 1,2 g/l, RBCs are leached and cover the whole vision field, granular casts - 1-2 in the vision field, salts are represented by urates (large quantity). What is the most likely diagnosis?

- A.** Acute glomerulonephritis with nephritic syndrome
- B.** Acute glomerulonephritis with nephrotic syndrome
- C.** Acute glomerulonephritis with nephrotic syndrome, hematuria and hypertension
- D.** Acute glomerulonephritis with isolated urinary syndrome
- E.** Nephrolithiasis

38. A 48-year-old patient has the following symptoms: diffuse enlargement of thyroid gland, exophthalmus, weight loss up to 4 kg within 2 months, excessive sweating. Objectively: heart rate 105/min, BP - 180/70 mm Hg. Stool is normal. What therapy is advisable in the given case?

- A.** Mercazolil (Thiamazole)
- B.** Potassium iodide
- C.** Propranolol
- D.** Iodomarin
- E.** Thyroxin

39. A patient is on sick leave for 4 months continuously from the date of injury. The

treatment is going to last for another 1-2 months. Who is authorised to extend the duration of medical certificate for this patient?

- A.** Medical advisory commission after medico-social expert commission examination
- B.** Medical superintendent
- C.** Medical advisory commission after inpatient treatment
- D.** District doctor by agreement with a department chief
- E.** Medico-social expert commission

40. A 30-year-old woman complains of pain in the heart area ("aching, piercing pain") that arises primarily in the morning hours in autumn and spring. Pain irradiates into the neck, back, abdomen and is attended by rapid heart rate and low vital tonus. This condition occurs independently from physical exertion. In the evening her condition improves. Somatic and neurologic state and ECG have no pathologies. What pathology is likely to result in such clinical presentation?

- A.** Somatized depression
- B.** Rest angina pectoris
- C.** Pseudoneurotic schizophrenia
- D.** Somatoform autonomic dysfunction
- E.** Hypochondriacal depression

41. A 59-year-old female patient attended a maternity welfare clinic with complains of bloody discharge from the genital tracts. Postmenopause is 12 years. Vaginal examination revealed that external genital organs had signs of age involution, uterus cervix was not erosive, small amount of bloody discharge came from the cervical canal. Uterus is of normal size, uterine appendages are unpalpable. Fornices were deep and painless. What method should be applied for the diagnosis specification?

- A.** Separated diagnostic curetage
- B.** Laparoscopy
- C.** Puncture of abdominal cavity through posterior vaginal fornix
- D.** Extensive colposcopy
- E.** Culdoscopy

42. A 41-year-old patient, a hunter, complains of heaviness in the right subcostal area. No other complaints recorded. Anamnesis states causeless urticaria and skin itching that occurred 1 year ago. Objectively: liver margin is rounded, painless, and can be palpated 3 cm below the costal arch. No other pathology was detected during physical examination of the patient. Body temperature is normal. X-ray reveals a hemispherical protrusion in the right cupula of the diaphragm. What disease can be suspected in the given case?

- A.** Hydatid disease of liver
- B.** Liver abscess
- C.** Hepatocellular carcinoma
- D.** Metastatic tumor
- E.** Subdiaphragmatic abscess

43. A 14-year-old girl has been presenting with irritability and tearfulness for about a year. A year ago she was also found to have diffuse enlargement of the thyroid gland (II grade). This condition was regarded as a pubertal manifestation, the girl did not undergo any treatment. The girl's irritability gradually gave place to a complete apathy. The girl got puffy face, soft tissues pastosity, bradycardia, constipations. Skin pallor and gland density progressed, the skin got a waxen hue. What disease may be assumed?

- A.** Autoimmune thyroiditis
- B.** Diffuse toxic goiter
- C.** Thyroid carcinoma
- D.** Subacute thyroiditis
- E.** Juvenile basophilism

44. A 26-year-old woman, who delivered a child 7 months ago, has been suffering from nausea, morning vomiting, sleepiness for the last 2 weeks. She breastfeeds the child, menstruation is absent. She has not applied any contraceptives. What method should be applied in order to specify her diagnosis?

- A.** Ultrasonic examination
- B.** X-ray of small pelvis
- C.** Palpation of mammary glands and pressing-out of colostrum
- D.** Bimanual vaginal examination
- E.** Speculum examination

45. Over a current year among workers of an institution 10% have not been ill a single time, 30% have been ill once, 15% - twice, 5% - 4 times, the rest - 5 and more times. What is the percentage of workers belonging to the I health group?

- A.** 55%
- B.** 10%
- C.** 40%
- D.** 60%
- E.** 22%

46. A 34-year-old patient after vacation in Crimea has developed severe pain in her elbow joints, dyspnea and weakness. Body temperature is $37,6^{\circ}C$, skin pallor and erythema on the cheeks and bridge of nose are observed, lip mucosa is ulcerated. The joints are not visibly deformed, movement of the right elbow joint is restricted. Pleura friction sound is detected in the lungs on the right side below the angle of scapula. Heart sounds are dull, tachycardia, gallop rhythm, heart rate - 114/min, BP - 100/60 mm Hg. The most likely diagnosis is:

- A.** Systemic lupus erythematosus
- B.** Rheumatic carditis
- C.** Rheumatoid arthritis
- D.** Infectious allergic myocarditis
- E.** Dry pleurisy

47. Several hours before, a 28-year-old patient suddenly developed acute headache and repeated vomiting, then lost consciousness.

Objectively: focal neurological symptoms were not found. Pronounced meningeal symptoms were revealed. BP - 120/80 mm Hg. According to clinical and liquorological findings the patient was diagnosed with subarachnoid haemorrhage. After administration of dehydrants the patient's condition somewhat improved. What is the main component of further emergency care?

- A.** Coagulants
- B.** Anticoagulants
- C.** Antiaggregants
- D.** Fibrinolytics
- E.** Corticosteroids

48. A 42-year-old man has undergone gastric analysis. Free hydrochloric acid is absent at all phases. On endoscopy: pallor, gastric mucosa loss, gastric folds are smoothed out. On microscopy: glands atrophy with intestinal metaplasia. What disease can be characterized by such presentation?

- A.** Chronic gastritis type A
- B.** Chronic gastritis type B
- C.** Chronic gastritis type C
- D.** Menetrier's disease
- E.** Stomach cancer

49. A 24-year-old woman, teacher by profession, complains of dizziness and heart pain irradiating to the left nipple. Pain is not associated with physical activity and cannot be relieved by nitroglycerin, it abates after taking Valocordin and lasts for an hour or more. The patient has a nearly 2-year history of this disease. Objectively: Heart rate - 76 bpm. BP - 110/70 mm Hg. Heart borders are normal, heart sounds are clear. The ECG shows respiratory arrhythmia. X-ray of the cervicothoracic spine shows no pathology. Lungs, abdomen are unremarkable. What changes in blood formula can be expected?

- A.** No changes
- B.** Leukocytosis
- C.** Thrombocytopenia
- D.** Leukemic hiatus
- E.** Increased ESR

50. Chief physician of a polyclinic tasked a district doctor with determining the pathological prevalence of disease N in his district. What document allows to estimate the disease prevalence in the population of a medical district?

- A.** Prophylactic examinations register
- B.** Statistic coupons (+)
- C.** Statistic coupons (-)
- D.** Statistic coupons (+) and (-)
- E.** Vouchers for medical appointments

51. A 32-year-old woman complains of dizziness, headache, palpitation, tremor. For the last several months she has been under outpatient monitoring for increased arterial pressure. Recently such attacks have become more frequent and severe. Objectively: skin

is covered with clammy sweat, tremor of the extremities is present. Heart rate - 110/min, BP - 220/140 mm Hg. Heart sounds are weakened. In blood: WBCs - $9,8 \cdot 10^9/l$, ESR - 22 mm/h. Blood glucose - 9,8 millimole/l. What disease is the most likely cause of this crisis?

- A. Pheochromocytoma
- B. Essential hypertension
- C. Preeclampsia
- D. Primary hyperaldosteronism
- E. Diabetic glomerulosclerosis

52. A 45-year-old patient complains of pain in the epigastric region, left subcostal area, abdominal distension, diarrhea, loss of weight. He has been suffering from this condition for 5 years. Objectively: tongue is moist with white coating near the root; deep palpation of abdomen reveals slight pain in the epigastric region and Mayo-Robson's point. Liver is painless and protrudes 1 cm from the costal arch. Spleen cannot be palpated. What disease can be primarily suspected?

- A. Chronic pancreatitis
- B. Atrophic gastritis
- C. Peptic stomach ulcer
- D. Chronic cholecystitis
- E. Chronic enteritis

53. A 58-year-old woman complains of spontaneous bruises, weakness, bleeding gums, dizziness. Objectively: the mucous membranes and skin are pale with numerous hemorrhages of various time of origin. Lymph nodes are not enlarged. Heart rate - 100/min, BP- 110/70 mm Hg. There are no changes of internal organs. Blood test results: RBC - $3,0 \cdot 10^{12}/l$, Hb - 92 g/l, colour index - 0,9, anisocytosis, poikilocytosis, WBC - $10 \cdot 10^9/l$, eosinophiles - 2%, stab neutrophiles - 12%, segmented neutrophiles - 68%, lymphocytes - 11%, monocytes - 7%, ESR - 12 mm/h. What laboratory test should be determined additionally to make a diagnosis?

- A. Platelets
- B. Reticulocytes
- C. Clotting time
- D. Osmotic resistance of erythrocytes
- E. Fibrinogen

54. After examination a 46-year-old patient was diagnosed with left breast cancer T2N2M0, clinical group II-a. What will be the treatment plan for this patient?

- A. Radiation therapy + operation + chemotherapy
- B. Operation only
- C. Operation + radiation therapy
- D. Radiation therapy only
- E. Chemotherapy only

55. In river-side urban community there was an outbreak of hepatitis type A possibly spread by water. What indexes of river water quality can confirm this theory?

- A. Coliphage number
- B. Colibacillus index
- C. Oxidability
- D. Non-icteric leptospirosis agent
- E. Fecal coliform bacteria index

56. A 25-year-old patient was delivered to an infectious diseases unit on the 3rd day of illness with complaints of headache, pain in lumbar spine and gastrocnemius muscles, high fever, chill. Objectively: condition of moderate severity. Scleras are icteric. Pharynx is hyperemic. Tongue is dry with dry brown coating. Abdomen is distended. Liver is enlarged by 2 cm. Spleen is not enlarged. Palpation of muscles, especially gastrocnemius muscles, is painful. Urine is dark in colour. Stool is normal in colour. The most likely diagnosis is:

- A. Leptospirosis
- B. Viral hepatitis type A
- C. Malaria
- D. Infectious mononucleosis
- E. Yersiniosis

57. A patient suffering from acute posttraumatic pain received an injection of morphine that brought him a significant relief. Which of the following mechanisms of action provided for antishock effect of morphine in this patient?

- A. Stimulation of opiate receptors
- B. Block of central cholinergic receptors
- C. Stimulation of benzodiazepine receptors
- D. Inhibition of dopamine mediation
- E. Intensification of GABA-ergic reactions

58. A 9-month-old child presents with fever, cough, dyspnea. The symptoms appeared 5 days ago after a contact with a person having URTI. Objectively: the child is in grave condition. Temperature of $38^{\circ}C$, cyanosis of nasolabial triangle is present. Respiration rate - 54/min, nasal flaring while breathing. There was percussion dullness on the right below the scapula angle, and tympanic sound over the rest of lungs. Auscultation revealed bilateral fine moist rales (crackles) predominating on the right. What is the most likely diagnosis?

- A. Acute pneumonia
- B. URTI
- C. Acute laryngotracheitis
- D. Acute bronchitis
- E. Acute bronchiolitis

59. A 50-year-old patient complains about having pain attacks in the right subcostal area for about a year. The pain arises mainly after taking fatty food. Over the last week the attacks occurred daily and became more painful. On the 3rd day of hospitalization the patient presented with icteritiousness of skin and scleras, light-coloured feces and dark urine. In blood: neutrophilic leukocytosis - $13,1 \cdot 10^9/l$, ESR - 28 mm/h. What is the most likely diagnosis?

- A. Chronic calculous cholecystitis
- B. Chronic recurrent pancreatitis
- C. Fatty degeneration of liver
- D. Chronic cholangitis, exacerbation stage
- E. Hypertensive dyskinesia of gallbladder

60. A 52-year-old woman complains of face distortion. It appeared 2 days ago after exposure to cold. Objectively: body temperature is $38,2^{\circ}\text{C}$. Face asymmetry is present. Frontal folds are flattened. Left eye is wider than the right one and cannot close. Left nasolabial fold is flattened, mouth corner is lowered. Examination revealed no other pathology. Blood count: leukocytes - $10 \cdot 10^9/\text{l}$, ESR - 20 mm/h. What is the most probable diagnosis?

- A. Facial neuritis
- B. Trigeminal neuralgia
- C. Hemicrania (migraine)
- D. Ischemic stroke
- E. Brain tumour

61. A 28-year-old female patient with a six-year history of Raynaud's syndrome has recently developed pain in the small joints of hands, difficult movement of food down the esophagus. What disease can be suspected in this case?

- A. Systemic scleroderma
- B. Periarteritis nodosa
- C. Rheumatoid arthritis
- D. Systemic lupus erythematosus
- E. Pseudotrichiniasis

62. An 8-year-old boy, who has been suffering from diabetes mellitus for 3 years, was delivered to a hospital in a condition of hyperglycemic coma. Primary dose of insulin should be prescribed basing on the following calculation:

- A. 0,1-0,2 units/kg of body mass per hour
- B. 0,05 units/kg of body mass per hour
- C. 0,2-0,3 units/kg of body mass per hour
- D. 0,3-0,4 units/kg of body mass per hour
- E. 0,4-0,5 units/kg of body mass per hour

63. A 43-year-old female patient complains of rash on the skin of her right leg, pain, weakness, body temperature rise up to 38°C . The disease is acute. Objectively: there is an edema on the skin of her right leg in the foot area, a well-defined bright red spot in the irregular shape of flame tips, which is hot to touch. There are isolated vesicles in the focus. What is your provisional diagnosis?

- A. Erysipelas
- B. Microbial eczema
- C. Contact dermatitis
- D. Toxicoderma
- E. Haemorrhagic vasculitis

64. A 47-year-old patient came to see a doctor on the 7th day of disease. The disease is acute: after the chill body temperature rose to 40°C and lasted up to 7 hours, then dropped abruptly, which caused profuse sweat. There were three such attacks occurring once every

other day. Two days ago the patient arrived from Africa. Objectively: pale skin, subicteric sclera, significantly enlarged liver and spleen. What is the cause of fever attacks in this disease?

- A. Erythrocytic schizogony
- B. Tissue schizogony
- C. Exotoxin of a causative agent
- D. Endotoxin of a causative agent
- E. Gametocytes

65. A 49-year-old patient 2 years ago was diagnosed with stage 1 silicosis. He complains of increased dyspnea and pain in the infrascapular regions. X-ray shows diffuse intensification and distortion of lung pattern with numerous nodular shadows 2-4 mm in diameter. Hardening of right interlobar pleura is detected. Lung roots are hardened and expanded. What X-ray type of pneumosclerosis does the patient have?

- A. Nodular
- B. Interstitial
- C. Interstitial-nodular
- D. Nodal
- E. Tumor-like

66. A 24-year-old patient complains of general weakness, dizziness, body temperature rise up to $37,5^{\circ}\text{C}$, sore throat, neck edema, enlargement of submaxillary lymph nodes. Objectively: mucous membrane of oropharynx is edematous and cyanotic, tonsils are enlarged and covered with films that spread beyond the tonsils and cannot be easily removed. What is the leading mechanism of this illness development?

- A. Action of bacterial exotoxin
- B. Action of bacterial endotoxin
- C. Allergic
- D. Accumulation of suboxidated products
- E. Bacteriemia

67. A 40-year-old woman with a history of combined mitral valve disease with predominant stenosis complains of dyspnea, asthma attacks at night, heart problems. At present, she is unable to do even easy housework. What is the optimal tactics of the patient treatment?

- A. Mitral commissurotomy
- B. Implantation of an artificial valve
- C. Antiarrhythmia therapy
- D. Treatment of heart failure
- E. Antirheumatic therapy

68. A 30-year-old woman with a long history of chronic pyelonephritis complains of considerable weakness, sleepiness, decrease in diuresis down to 100 ml per day. BP is 200/120 mm Hg. In blood: creatinine - 0,62 millimole/l, hypoproteinemia, albumines - 32 g/l, potassium - 6,8 millimole/l, hypochromic anemia, increased ESR. What is the first step in the patient treatment tactics?

- A. Haemodialysis
- B. Antibacterial therapy
- C. Enterosorption
- D. Haemosorption
- E. Blood transfusion

69. A 43-year-old patient had right-sided deep vein thrombosis of iliofemoral segment 3 years ago. Now he is suffering from the sense of heaviness, edema of the lower right extremity. Objectively: moderate edema of shin, brown induration of skin in the lower third of shin, varix dilatation of superficial shin veins are present. What is the most probable diagnosis?

- A. Postthrombophlebitic syndrome, varicose form
- B. Acute thrombosis of right veins
- C. Lymphedema of lower right extremity
- D. Parkes-Weber syndrome
- E. Acute thrombophlebitis of superficial veins

70. A 28-year-old woman has bursting pain in the lower abdomen during menstruation; chocolate-like discharges from vagina are observed. It is known from the anamnesis that the patient suffers from chronic adnexitis. Bimanual examination revealed a tumour-like formation of heterogenous consistency 7x7 cm large to the left from the uterus. The formation is restrictedly movable, painful when moved. What is the most probable diagnosis?

- A. Endometrioid cyst of the left ovary
- B. Follicular cyst of the left ovary
- C. Fibromatous node
- D. Exacerbation of chronic adnexitis
- E. Tumour of sigmoid colon

71. A 6-year-old child complains of frequent liquid stool and vomiting. On the 2nd day of disease the child presented with inertness, temperature rise up to 38,2°C, heart rate - 150 bpm, scaphoid abdomen, palpatory painful sigmoid colon, defecation 10 times a day with liquid, scarce stool with mucus and streaks of green. What is a provisional diagnosis?

- A. Shigellosis
- B. Salmonellosis
- C. Escherichiosis
- D. Intestinal amebiasis
- E. Yersiniosis

72. A 65-year-old patient complains of pain in the lumbar spine, moderate disuria. He has been suffering from this condition for about half a year. Prostate volume is 45 cm³ (there are hypoechogenic nodes in both lobes, capsule invasion). Prostate-specific antigen is 60 ng/ml. Prostate biopsy revealed an adenocarcinoma. Which of the supplementary examination methods will allow to determine the stage of neoplastic process in this patient?

- A. Computer tomography of small pelvis
- B. Lumbar spine X-ray
- C. Excretory urography
- D. Bone scintigraphy
- E. Chest X-ray

73. A 12-year-old child has been hit on the stomach. The patient is in moderately grave condition, has a forced position in bed. The skin is pale, heart rate - 122/min. Stress on the left costal arch causes a slight pain. Weirner and Kulenkampff symptoms are positive. Macroscopically the urine is unchanged. What is the most likely diagnosis?

- A. Spleen rupture, abdominal bleeding
- B. Left kidney rupture, retroperitoneal hematoma
- C. Rupture of the pancreas
- D. Liver rupture, abdominal bleeding
- E. Rupture of a hollow organ, peritonitis

74. Establishments participating in medical examinations include: medical and preventive treatment facility, hygiene and preventive treatment facility, sociomedical expert committees, Ministry of Defence medical committees, Ministry of Domestic Affairs medical committees, forensic medicine agency, etc. Specify what service deals with sociomedical assessment of temporary disability:

- A. Medical and preventive treatment facility
- B. Hygiene and preventive treatment facility
- C. Sociomedical expert committees
- D. Ministry of Defence medical committees
- E. Ministry of Domestic Affairs medical committees

75. An unconscious 35-year-old patient has been delivered by an ambulance to the intensive care unit. Objectively: the patient is in semicoma. Moderate mydriasis is present. The reaction of pupils to light is reduced. The patient is non-responsive to verbal instructions. BP is 150/100 mm Hg, tachycardia is present. Blood contains methanol. What antidote should be administered?

- A. Ethanol
- B. Unithiol
- C. Thiamine chloride
- D. Tavegil (Clemastine)
- E. Naloxone

76. After lifting a load, a 36-year-old male patient has experienced a severe pain in the lumbar region, which spread to the right leg and was getting worse when he moved his foot or coughed. Objectively: the long back muscles on the right are strained. Achilles jerk is reduced on the right. There is a pronounced tenderness of paravertebral points in the lumbar region. The straight leg raise (Lasegue's sign) is positive on the right. What additional tests should be performed in the first place?

- A. Radiography of the spinal column
- B. Computed tomography
- C. Magnetic resonance tomography
- D. Electromyography
- E. Lumbar puncture

77. A patient is active, lively, fussy. He resists the examination. His speech is fast and loud, his statements are spontaneous and

inconsequent. Specify the psychopathological state of this patient:

- A. Psychomotor agitation
- B. Catatonic agitation
- C. Delirium
- D. Behavioral disorder
- E. Paranoid syndrome

78. A 4-year-old boy was vaccinated in violation of his vaccination schedule. There are complaints of pain in the throat during swallowing, headache, inertness, fever. Objectively: the child is pale; anterior cervical lymph nodes are enlarged; tonsils are swollen, with cyanotic hyperemia, and covered with grey-white coating that cannot be removed; if it is forcibly removed, tonsils bleed. The most likely diagnosis is:

- A. Oropharyngeal diphtheria
- B. Lacunar tonsillitis
- C. Pseudomembranous (Vincent's) tonsillitis
- D. Infectious mononucleosis
- E. Follicular tonsillitis

79. A 26-year-old male patient complains of piercing pain during breathing, cough, dyspnea. Objectively: t° - $37,3^{\circ}C$, respiration rate is 19/min, heart rate is 92/min; BP is 120/80 mm Hg. Vesicular respiration is observed. In the inferolateral parts of chest auscultation in both inspiration and expiration phase revealed noise that was getting stronger at phonendoscope pressing and could be still heard after cough. ECG showed no pathological changes. What is the most likely diagnosis?

- A. Acute pleuritis
- B. Intercostal neuralgia
- C. Subcutaneous emphysema
- D. Spontaneous pneumothorax
- E. Pericarditis sicca

80. A child is 3-week-old. Since his birth periodical vomiting is observed occurring several minutes after feeding. Vomit mass does not exceed previous feeding volume. Body mass is appropriate to the child's age. What is the most likely cause for the symptoms described?

- A. Pylorospasm
- B. Esophageal chaliasia
- C. Adrenogenital syndrome
- D. Pylorostenosis
- E. Esophageal achaliasia

81. A 30-year-old parturient woman was delivered to a maternity hospital with full-term pregnancy. She complains of severe lancinating pain in the uterus that started 1 hour ago, nausea, vomiting, cold sweat. Anamnesis states cesarean section 2 years ago. Uterine contractions stopped. Skin and mucous membranes are pale. Heart rate is 100/min, BP is 90/60 mm Hg. Uterus has no clear margins, is sharply painful. No heartbeat can be auscultated in the fetus. Moderate bloody discharge from the uterus can be observed. Uterus cervix is 4 cm open. Presenting part is not visible. The most likely

diagnosis is:

- A. Uterine rupture
- B. Initial uterine rupture
- C. Threatened uterine rupture
- D. Premature detachment of normally positioned placenta
- E. Compression of inferior pudendal vein

82. A 26-year-old female patient has an 11-year history of rheumatism. Four years ago she suffered 2 rheumatic attacks. Over the last 6 months there have been paroxysms of atrial fibrillation every 2-3 months. What option of antiarrhythmic therapy or tactics should be proposed?

- A. Prophylactic administration of cordarone
- B. Immediate hospitalization
- C. Defibrillation
- D. Lidocaine administration
- E. Heparin administration

83. A 47-year-old female patient complains of cough with purulent sputum, pain in the lower left chest, periodical body temperature rise. She has been suffering from this condition for about 10 years. Objectively: "drumstick" distal phalanges. What examination would be the most informative for making a diagnosis?

- A. Bronchography
- B. Bronchoscopy
- C. Survey radiograph of lungs
- D. Pleural puncture
- E. Bacteriological analysis of sputum

84. A patient is 60-year-old, retired, worked as deputy director of a research institute. Behavioural changes appeared 2 years ago after the death of her husband: she stopped looking after herself and leaving the house; then she stopped to clean the apartment and cook. Mental status: temporal disorientation. The patient does not understand many of the questions, is confused; does not know how to cook soup or fasten a button. Her speech is characterized by stumbling and logoclonia. She does not recognize doctors, fellow patients. She cries a lot but can not explain the reason for tears. What is the mechanism of this pathology?

- A. Atrophy of the cerebral cortex
- B. Atherosclerotic changes in cerebral vessels
- C. Serotonin deficiency
- D. Impaired conversion of dopamine to noradrenaline
- E. Disorder of melatonin metabolism

85. An 8-year-old girl periodically has sudden short-term heart pain, sensation of chest compression, epigastric pain, dizziness, vomiting. Objectively: the patient is pale, respiratory rate - 40/min, jugular pulse is present. Heart rate - 185 bpm, of poor volume. BP - 75/40 mm Hg. ECG taken during an attack shows ectopic P waves, QRS wave is not deformed. At the end of an attack a compensatory pause is observed. The most likely cause of the attack

is:

- A. Paroxysmal atrial tachycardia
- B. Sinus tachycardia
- C. Paroxysmal ventricular tachycardia
- D. Complete AV-block
- E. Atrial fibrillation

86. During examination a patient is unconscious, his skin is dry and hot, face hyperemia is present. The patient has Kussmaul's respiration, there is also smell of acetone in the air. Symptoms of peritoneum irritation are positive. Blood sugar is 33 millimole/l. What emergency actions should be taken?

- A. Intravenous infusion of short-acting insulin
- B. Intravenous infusion of glucose along with insulin
- C. Introduction of long-acting insulin
- D. Intravenous infusion of neohaemodesum along with glutamic acid
- E. Intravenous infusion of sodium chloride saline

87. A patient complains of evaginations in the region of anus that appear during defecation and need resetting. Examination with anoscope revealed 1x1 cm large evaginations of mucosa above the pectineal line. What is the most probable diagnosis?

- A. Internal hemorrhoids
- B. Acute paraproctitis
- C. External hemorrhoids
- D. Anal fissure
- E. -

88. During the newborn infant's examination redness of the skin was detected, which occurred immediately after birth and became the most pronounced on the second day of the infant's life. What provisional diagnosis can be made?

- A. Simple erythema
- B. Toxic erythema
- C. Transient erythema
- D. Erythema nodosum
- E. Erythema anulare centrifugum

89. A baby was born by a young smoker. The labour was complicated by uterine inertia, difficult delivery of the baby's head and shoulders. The baby's Apgar score was 4. Which of the following is a risk factor for a spinal cord injury?

- A. Difficult delivery of the head and shoulders
- B. Young age of the mother
- C. Pernicious habits
- D. Uterine inertia
- E. Chronic hypoxia

90. In order to study impact of microclimate on the human organism it is necessary to make systematic observation of air temperature during the period of 3 days. Choose a device that will allow to make the most precise temperature records:

- A. Thermograph
- B. Alcohol thermometer
- C. Mercury thermometer
- D. August's psychrometer
- E. Assmann psychrometer

91. Against the background of angina a patient has developed pain in tubular bones. Examination revealed generalized enlargement of lymph nodes, hepatolienal syndrome, sternalgia. In blood: RBCs - $3,6 \cdot 10^{12}/l$, Hb - 87 g/l, thrombocytes - $45 \cdot 10^9/l$, WBCs - $13 \cdot 10^9/l$, blasts - 87%, stab neutrophils - 1%, segmented neutrophils - 7%, lymphocytes - 5%, ESR - 55 mm/h. What is the most likely diagnosis?

- A. Acute leukemia
- B. Erythremia
- C. Chronic lymphocytic leukemia
- D. Chronic myeloid leukemia
- E. Multiple myeloma

92. For a long time to eradicate weeds on agricultural lands herbicides retaining in environment have been used. Point out the most probable way of herbicides reaching human organism from soil:

- A. Soil-plants-human
- B. Soil-microorganisms-human
- C. Soil-animals-human
- D. Soil-protozoa-human
- E. Soil-insects-human

93. A 52-year-old patient complains of pain in the right part of her chest, dyspnea, cough with a lot of albuminoid sputum emitting foul smell of "meat slops". Objectively: the patient's condition is grave, cyanosis is observed, breathing rate is 31/min, percussion sound above the right lung is shortened, auscultation revealed various moist rales (crackles). What is the most probable diagnosis?

- A. Lung gangrene
- B. Lung abscess
- C. Pleura empyema
- D. Multiple bronchiectasis
- E. Chronic pneumonia

94. A 15-year-old patient suffers from headache, nasal haemorrhages, sense of lower extremity coldness. Objectively: muscles of shoulder girdle are developed, lower extremities are hypotrophied. Pulsation on the pedal and femoral arteries is sharply dampened. BP is 150/90 mm Hg, 90/60 in the legs. Systolic murmur can be auscultated above carotid arteries. What is the most probable diagnosis?

- A. Aorta coarctation
- B. Aorta aneurism
- C. Aortal stenosis
- D. Aortal insufficiency
- E. Coarctation of pulmonary artery

95. A patient with frostbite of both feet was delivered to an admission ward. What actions should be taken?

- A. To apply a bandage, to introduce vasodilating medications
- B. To administer cardiac medications
- C. To put feet into hot water
- D. To rub feet with snow
- E. To apply an alcohol compress

96. A patient in a clinical death condition is being resuscitated through mouth-to-mouth artificial pulmonary ventilation and external cardiac massage. A doctor noticed that air does not flow into the patient's airways and his head and torso are positioned at the same level. Why is artificial respiration not effective in the given case?

- A. Tongue retraction
- B. Low breathing volume
- C. External cardiac massage
- D. Probe is absent from stomach
- E. The patient's mouth is too small

97. Hygienic assessment of a sample taken from the batch of grain revealed 2% of grains infected with microscopic *Fusarium* fungi. On the grounds of laboratory analyses this batch of grain should be:

- A. Sold without restrictions
- B. Tested for toxicity
- C. Used for forage production
- D. Used for ethanol production
- E. Destroyed

98. Residents of an industrial community situated near a plant suffer from increased morbidity rate caused by nervous and endocrine system conditions and kidney diseases. Blood test: decrease of sulfhydryl groups content in blood. The pathologies developed can be caused by environment being polluted by the following:

- A. Mercury
- B. Cadmium
- C. Boron
- D. Chromium
- E. Lead

99. Various population groups mortality has been studied for a long time; territorial distribution of population and resulting changes in mortality trends are considered. What statistical method can be applied?

- A. Time series analysis
- B. Standardized ratio analysis
- C. Correlation and regression analysis
- D. Assessment of parameter difference reliability
- E. Analysis of relative values

100. A 45-year-old patient with urolithiasis had an attack of renal colic. What is the mechanism of the attack development?

- A. Disturbed urine outflow from the kidney
- B. Increase in urine specific gravity
- C. Ureteric twists
- D. Destruction of renal glomerules
- E. Renal artery spasm

101. A 26-year-old woman has attended maternity center complaining of her inability to become pregnant despite 3 years of regular sex life. Examination revealed the following: increased body weight; male-type pubic hair; excessive pilosity of thighs; ovaries are dense and enlarged; basal body temperature is monophasic. The most likely diagnosis is:

- A. Ovaries sclerocystosis
- B. Inflammation of uterine appendages
- C. Adrenogenital syndrome
- D. Premenstrual syndrome
- E. Gonadal dysgenesis

102. A workshop resident doctor makes a list of workers, who are often ill, for special supervision. He takes into account the number of etiologically connected cases resulting in temporary disability that occurred in the span of a year for each worker. How many such cases should a worker have to be included in this group?

- A. 4 and more
- B. 1 and more
- C. 2 and more
- D. 3 and more
- E. 6 and more

103. A 28-year-old woman complains of increased intermenstrual periods up to 2 months, hirsutism. Gynaecological examination revealed that the ovaries were enlarged, painless, compact, uterus had no peculiarities. Pelvic ultrasound revealed that the ovaries were 4-5 cm in diameter and had multiple enlarged follicles on periphery. X-ray of skull base showed that sellar region was dilated. What is the most probable diagnosis?

- A. Stein-Leventhal syndrome (Polycystic ovary syndrome)
- B. Algodismenorrhea
- C. Sheehan's syndrome
- D. Premenstrual syndrome
- E. Morgagni-Stewart syndrome

104. A woman consulted a therapist about fatigability, significant weight loss, weakness, loss of appetite. She has been having amenorrhea for 8 months. A year ago she born a full-term child. Haemorrhage during labour made up 2 l. She got blood and blood substitute transfusions. What is the most probable diagnosis?

- A. Sheehan's syndrome
- B. Stein-Leventhal syndrome
- C. Shereshevsky-Turner's syndrome
- D. Homological blood syndrome
- E. Vegetovascular dystonia

105. The correlation between service record

and eosinophiles concentration in blood was studied in workers at dyeing shops of textile factories. What index will be the most informative for the analysis of this data?

- A. Correlation factor
- B. Student's criterion
- C. Standardized index
- D. Fitting criterion
- E. Sign index

106. A 39-year-old woman suffering from schizophrenia constantly strains to hear something insisting that "there is a phone connection in her brain and she hears her brother's voice demanding that she come back home". The patient is anxious, suspicious, constantly looking around. Specify the psychopathologic syndrome.

- A. Hallucinatory
- B. Anxiety
- C. Paranoid
- D. Paraphrenic
- E. Depressive

107. A 3-month-old girl has rhinitis, dyspnea, dry cough. She has been sick for 2 days. Objectively: pale skin, acrocyanosis, hypopnoe; breathing rate is 80/min; over the whole pulmonary surface there is vesiculotympanic (bandbox) resonance observed with numerous bubbling rales (crackles). The most likely diagnosis is:

- A. Acute bronchiolitis
- B. Pneumonia
- C. Mucoviscidosis
- D. Foreign body in airways
- E. Acute bronchitis

108. A 30-year-old patient was hospitalised in an intensive care unit with a diagnosis of multiple bee stings. Skin is pale and covered with cold sweat. Pulse can be palpated only at the carotid arteries and is 110/min; breathing rate is 24/min, rhythmical, weakened. What drug must be administered immediately?

- A. Adrenaline hydrochloride intravenously
- B. Prednisolone intravenously
- C. Adrenaline hydrochloride intramuscularly
- D. Dopamine intravenously
- E. Tavegil (Clemastine) intravenously

109. A 24-year-old patient complains of gaining body mass and increased appetite. Objectively: built of hypersthenic type, body mass index is $33,2 \text{ kg/m}^2$, waist circumference is 100 cm. Waist to hips circumference ratio is 0,95. What is the provisional diagnosis?

- A. Alimentary constitutive obesity, I stage, android type
- B. Itsenko-Cushing hypothalamic obesity, II stage, gynoid type
- C. Alimentary constitutive obesity, III stage, gynoid type
- D. Alimentary constitutive obesity, II stage, android type
- E. Itsenko-Cushing hypothalamic obesity, I stage, android type

110. A parturient woman is 27 year old, it was her second labour, delivery was at full-term, normal course. On the 3rd day of postpartum period body temperature is $36,8^{\circ}\text{C}$, heart rate - 72/min, BP - 120/80 mm Hg, Mammary glands are moderately swollen, nipples are clean. Abdomen is soft and painless. Fundus of uterus is 3 fingers below the umbilicus. Lochia are bloody, moderate. What is the most probable diagnosis?

- A. Physiological course of postpartum period
- B. Subinvolution of uterus
- C. Postpartum metroendometritis
- D. Remnants of placental tissue after labour
- E. Lactostasis

111. A 40-year-old patient suffers from influenza. On the 5th day of illness there are pain behind sternum, cough with sputum, inertness. Temperature is $39,5^{\circ}\text{C}$. Face is pale. Mucosa of conjunctivas and pharynx is hyperemic. Heart rate is 120/min, breathing rate is 38/min. In the lower lung segments shortening of percussion sound and moist rales (crackles) can be detected. What additional investigation should be performed first of all to specify the diagnosis?

- A. Lung X-ray
- B. ECG
- C. Heart US
- D. Mantoux test
- E. Spirography

112. A 45-year-old patient complains of body temperature rise up to 40°C , general weakness, headache, painfulness and spastic muscle contractions around the wound in the shin. He received this wound 5 days ago when working in his garden. He requested no medical care back then. What wound infection can be suspected?

- A. Tetanus
- B. Anthrax
- C. Erysipelas
- D. Gram-positive
- E. Gram-negative

113. A 60-year-old woman started feeling weakness, vertigo, rapid fatigability during the last year. Recently there have been dyspnea and paresthesia observed. Objectively: skin and mucous membranes are pale and icteric. Lingual papillae are smoothed out. Liver and spleen are situated at the edge of costal arch. Blood test: Hb- 70 g/l, erythrocytes - $1,7 \cdot 10^{12}/l$, blood color index - 1,2, macrocytes. What drug

can be prescribed on pathogenetic grounds?

- A. Vitamin B_{12}
- B. Vitamin B_6
- C. Ascorbic acid
- D. Iron preparations
- E. Vitamin B_1

114. A 34-year-old patient complains of profuse sweating at night, skin itching, weight loss (9 kg within the last 3 months). Examination revealed malnutrition, skin pallor. Palpation of neck and inguinal areas revealed dense elastic lymph nodes of about 1 cm in diameter, nonmobile, non-adhering to skin. What is the most probable diagnosis?

- A. Lymphogranulomatosis
- B. Chronic lymphadenitis
- C. Lymphosarcoma
- D. Burkitt's lymphoma
- E. Cancer metastases

115. A 57-year-old woman complains of having a sensation of esophageal compression, palpitation, breathing difficulties when eating solid food, occasional vomiting with a full mouth, "wet pillow" sign at night for the last 6 months. Objectively: body temperature - $39^{\circ}C$, height - 168 cm, weight - 72 kg, heart rate - 76/min, BP-120/80 mm Hg. X-ray revealed considerable dilation of esophagus and its constriction in the cardiac part. What pathology is most likely to have caused dysphagia in this patient?

- A. Achalasia cardiae
- B. Primary esophagism
- C. Hiatal hernia
- D. Esophageal carcinoma
- E. Reflux esophagitis

116. A 25-year-old man complains of pain in the lower third of his left thigh, which occurs both with and without physical exertion. Possibility of trauma is denied by the patient. Objectively: skin colour is normal; pastosity and pain can be detected with deep palpation; knee joint mobility is reduced. X-ray of distal femoral metaphysis shows an area of destruction and spicule. Blood test: immature cells, no signs of inflammation. The most likely diagnosis is:

- A. Osteogenic sarcoma
- B. Osteitis fibrosa cystica
- C. Chronic osteomyelitis
- D. Multiple myeloma
- E. Marble-bone disease

117. A 37-year-old woman complains of sharp pains in her external genitalia, edema of the vulvar lips, pain when walking. Objectively: body temperature is $38,7^{\circ}C$, heart rate is 98/min. Inside the right vulvar lip there is a dense, painful, tumor-like growth 5,0x4,5 cm in size; skin and mucosa of the external genitalia are hyperemic, copious foul-smelling discharge is observed. The most likely diagnosis is:

- A. Acute bartholinitis
- B. Furuncle of outer labia
- C. Acute vulvovaginitis
- D. Bartholin's cyst
- E. Carcinoma of vulva

118. In a rural health care area there is a case of child dying during the first month of his life. To analyse this situation, among other measures, an expert assessment of medical records is performed. What medical document should be considered first?

- A. Child development history
- B. Infant development history
- C. Vaccination card
- D. Outpatient medical record
- E. Child's medical record

119. Examination of placenta revealed a defect. An obstetrician performed manual investigation of uterine cavity, uterine massage. Prophylaxis of endometritis in the postpartum period should involve the following actions:

- A. Antibacterial therapy
- B. Instrumental revision of uterine cavity
- C. Haemostatic therapy
- D. Contracting agents
- E. Intrauterine instillation of dioxine

120. A 15-year-old boy has developed pain in the area of his left knee joint. Objectively: thigh soft tissues in the painful area are infiltrated, joint function is reduced. X-ray: there is a focus of destruction in the left distal femoral metaphysis, with periosteum detachment and formation of Codman triangle in the bone cortical layer at the margin of the defect. Chest X-ray reveals numerous microfocal metastases. What pathology is the most likely to cause such presentation?

- A. Osteogenic sarcoma
- B. Fibrosarcoma
- C. Chondrosarcoma
- D. Ewing's sarcoma
- E. Juxtacortical sarcoma

121. A 74-year-old man complains of pain in the left foot and dark color of the 1st toe. He has been sick for 6 days. Objectively: heart rate is 84/min. Body temperature is $37,8^{\circ}C$. The left foot resembles "chicken claw" due to soft tissues decreasing in volume, skin is dark red. The 1st toe is black, small amount of dark substance is being discharged from under the nail. Pulse over the peripheral arteries of extremity is absent. The most likely diagnosis is:

- A. Gangrene
- B. Phlegmon
- C. Panaritium
- D. Erysipelas
- E. Erysipeloid

122. Head circumference of a 1-month-old boy with signs of excitement is 37 cm, prefontanel is 2x2 cm large. After feeding the child regurgitates small portions of milk; stool is normal

in its volume and composition. Muscle tone is within norm. What is the most likely diagnosis?

- A. Pylorospasm
- B. Meningitis
- C. Pylorostenosis
- D. Microcephaly
- E. Craniostenosis

123. A 49-year-old patient complains of difficulties when swallowing food, hoarse voice, weight loss. The patient has been suffering from these symptoms for the last 3 months. The symptoms are gradually progressing. Objectively: the patient is emaciated, supraclavicular lymph nodes are enlarged. Esophagoscopy revealed no pathologies of esophagus. What investigation would be the most advisable in the given case?

- A. Computed tomogram of chest and mediastinum
- B. Lungs X-ray
- C. Multiplanar fluoroscopy of esophagus
- D. Radioisotopic examination of chest and mediastinum
- E. US of mediastinum

124. A 36-year-old male patient complains of having headache, obstructed nasal breathing, purulent nasal discharge for 2 weeks. A month before, he had his right maxillary premolar filled. X-ray revealed an intense opacity of the right maxillary sinus. Diagnostic puncture revealed a large amount of thick malodorous crumbly pus. What is the most likely diagnosis?

- A. Chronic suppurative odontogenic sinusitis
- B. Acute purulent sinusitis
- C. Chronic purulent sinusitis
- D. Chronic atrophic sinusitis
- E. Tumor of the maxillary sinus

125. During a surgical operation necessitated by the patient's suffering from autoimmune thyroiditis with concomitant multinodular goiter the right lobe was removed and subtotal resection of the left lobe was performed. What should be prescribed to the patient for postoperative hypothyroidism prevention?

- A. L-thyroxin
- B. Mercazolil (Thiamazole)
- C. Iodomarin (Potassium iodide)
- D. Lithium preparations
- E. Insulin

126. A 54-year-old patient has been suffering from diabetes mellitus for 5 years, with diet being his only treatment. Within the last half a year he lost 7 kg of body weight, complains of thirst, vertigo when raising from bed, decrease of erectile function, frequent stool, especially at night. Objectively: malnutrition, dry skin. BP in lying position is 160/90 mm Hg; BP in standing position is 170/85 mm Hg. No edemas. Fasting plasma glucose level is 12 mmol/l. Glycated hemoglobin accounts for 11%. Albumin excreted with urine is 20 mg per day. The most likely diagnosis is:

- A. Diabetes mellitus type 2 with visceral neuropathy
- B. Diabetes mellitus type 1 with ketoacidosis
- C. Diabetes mellitus type 1 with encephalomyelopathy
- D. Diabetes mellitus type 2 with nephropathy
- E. Diabetes mellitus type 2 with polyneuropathy

127. A young woman suffering from seborrhea oleosa has numerous light-brown and white spots on the skin of her torso and shoulders. The spots have clear margins, branny desquamation, no itching. What provisional diagnosis can be made?

- A. Pityriasis versicolor
- B. Torso dermatophytosis
- C. Seborrheic dermatitis
- D. Pityriasis rosea
- E. Vitiligo

128. 10 days after birth an infant developed a sudden fever up to 38,1°C. Objectively: the skin of navel, abdomen and chest is erythematous; there are multiple pea-sized blisters with no infiltration at the base; single bright red moist erosions with epidermal fragments on the periphery. What is your provisional diagnosis?

- A. Epidemic pemphigus of newborn
- B. Syphilitic pemphigus
- C. Streptococcal impetigo
- D. Vulgar impetigo
- E. Atopic dermatitis

129. In a traffic accident two persons died. An appointed forensic medical expert was called on duty to another accident location; therefore, according to the criminal law in force in Ukraine, an investigator called in the following specialist for examination of the location and bodies:

- A. Nearest available medical doctor
- B. Medical assistant
- C. Surgical nurse
- D. Nearest available dispensing chemist
- E. Nearest available dental mechanic

130. A 35-year-old female patient has gained 20 kg weight within a year with the normal diet. She complains of chill, sleepiness, dyspnea. The patient's mother and sister are corpulent. Objectively: height - 160 cm, weight - 92 kg, BMI - 35,9. Obesity is uniform, there are no striae. The face is amimic. The skin is dry. The tongue is thickened. Heart sounds are muffled. Heart rate - 56/min, BP - 140/100 mm Hg. The patient has constipations, amenorrhea for 5 months. TSH - 28 mkME/l (normal rate - 0,32-5). Craniogram shows no pathology. What is the etiology of obesity?

- A. Hypothyroid
- B. Hypo-ovarian
- C. Hypothalamic-pituitary
- D. Alimentary and constitutive
- E. Hypercorticoid

131. A 45-year-old patient has been suffering from essential hypertension for 10 years. After hot bath he suddenly developed sharp headache and recurrent vomiting. Objectively: pronounced meningeal symptoms; BP is 180/110 mm Hg. He was hospitalised in a neurology unit. What additional tests should be primarily prescribed?

- A. Lumbar puncture, cerebrospinal fluid test
- B. Ventriculopuncture
- C. Echoencephalography
- D. Rheoencephalography
- E. Electroencephalography

132. A 77-years-old patient complains of inability to urinate and bursting pain above his pubis. Acute onset of his condition occurred 12 hours ago. Objectively: overfilled urinary bladder can be palpated above the pubis. On rectal examination: prostate is enlarged, dense-elastic, with clear margins and no nodules. Interlobar sulcus is pronounced. US examination: prostate volume is 120 cm³, it protrudes into urinary bladder cavity, parenchyma is homogeneous. Prostate specific antigen is 5 ng/ml. What disease is the most likely to cause acute urinary retention?

- A. Prostatic hyperplasia
- B. Prostate cancer
- C. Prostate sclerosis
- D. Prostate tuberculosis
- E. Acute prostatitis

133. A patient with uterine fibromyoma sized up to 8-9 weeks of pregnancy consulted a gynaecologist about acute pain in the lower abdomen. Examination revealed pronounced positive symptoms of peritoneal irritation, high leukocytosis. Vaginal examination revealed that the uterus was enlarged up to 9 weeks of pregnancy due to the fibromatous nodes, one of which was mobile and extremely painful. Appendages were not palpable. Discharges were mucous, coming in moderate amounts. What is the treatment tactics?

- A. Urgent surgery (laparotomy)
- B. Surveillance and spasmolytic therapy
- C. Fractional diagnostic curettage of the uterine cavity
- D. Surgical laparoscopy
- E. Surveillance and antibacterial therapy

134. A 4-month-old child was admitted to a surgical department 8 hours after the first attack of anxiety. The attacks happen every 10 minutes and last for 2-3 minutes, vomiting occurred once. Objectively: the child's condition is grave. Abdomen is soft, palpation reveals a tumour-like formation in the right iliac area. After rectal examination the doctor's finger was stained with blood. What is the most probable diagnosis?

- A. Ileocecal invagination
- B. Gastrointestinal haemorrhage
- C. Wilm's tumour
- D. Helminthic invasion
- E. Pylorostenosis

135. A 68-year-old patient complains of pain, slight swelling and creaking in the distal joints of her fingers and knee joints. She has been suffering from this condition for 4 years. Objectively: thickening of knee and interphalangeal joints, restricted mobility of these joints. Blood test: leukocytes - $5,4 \cdot 10^9/l$, ESR - 12 mm/h, fibrinogen - 3,5 g/l; Rheumatoid factor - 1:32; anti-streptolysin O - 160 units; seromuroid - 0,20 units.; CRP+. What mechanism of development is likely for this condition?

- A. Glycosaminoglycanes synthesis disruption
- B. Rheumatoid factor development
- C. Native DNA antibodies hyperproduction
- D. Increased uric acid sunthesis
- E. Immune reaction to streptococcosis

136. A 30-year-old male patient consulted a family doctor 2 months after he had been operated for an open fracture of brachial bone. Objectively: the patient's condition is satisfactory; in the area of the operative wound there is a fistula with some purulent discharge, redness, fluctuation. X-ray image shows brachial bone destruction with sequestra. What complication arose in the postoperative period?

- A. Posttraumatic osteomyelitis
- B. Hematogenic osteomyelitis
- C. Wound abscess
- D. Posttraumatic phlegmon
- E. Suture sinus

137. A 40-year-old female patient complains of having a bulge on the anterior surface of neck for 5 years. Objectively: Heart rate - 72 bpm, arterial pressure - 110/70 mm Hg, in the right lobe of thyroid gland palpation reveals a mobile 4x2 cm node, the left lobe is not palpable, the basal metabolic rate is 6%. What is the most likely diagnosis?

- A. Nodular euthyroid goiter
- B. Nodular hyperthyroid goiter
- C. Riedel's thyroiditis
- D. Mixed euthyroid goiter
- E. The median cervical cyst

138. Estimation of community health level involved analysis of a report on diseases registered among the population of catchment area (reporting form 12). What index is calculated basing on this report?

- A. Common morbidity rate
- B. Index of pathological affection
- C. Index of morbidity with temporary disability
- D. Index of hospitalized morbidity
- E. Index of basic non-epidemic morbidity

139. A tractor driver with the record of servi-

ce of 24 years has undergone palestesiometry test (Vibration Sensitivity Measurement). Test revealed increased vibration sensitivity threshold at the frequencies of 63-125-259 Hz to 25 dB. Dynamometry is 20 kg on the right and 16 kg on the left. Cold stimulus test is positive, time of hand temperature restoration is 52 minutes. Blanching at pressure symptom is positive and equals 21. Hypesthesia of upper and lower limbs is observed and can be classified as "gloves" and "socks" polyneuritic pattern. Make the provisional diagnosis.

- A. Vibration disease, I stage, caused by combined vibration
- B. Vibration disease, I stage, caused by local vibration
- C. Vibration disease, II stage, caused by combined vibration
- D. Vibration disease, II stage, caused by local vibration
- E. Vibration disease, I stage, caused by general vibration

140. A patient's X-ray image (anteroposterior projection) shows deformation of lung pattern, pneumofibrosis, reticular (honeycomb) lung pattern of lower pulmonary segments, cylindrical and fusiform lumps. The most likely diagnosis is:

- A. Multiple bronchiectasis
- B. Right lung abscess
- C. Non-hospital-acquired pneumonia
- D. Lungs maldevelopment
- E. Diffuse pulmonary fibrosis

141. A 41-year-old patient with Addison's disease had influenza. After that he developed adynamia, depression, nausea, vomiting, diarrhea and hypoglycemia. BP is 75/50 mm Hg. Blood test: decreased content of corticosterone, hydrocortisone, 13-oxycorticosteroids, 17-oxycorticosteroids. What condition has developed in the patient?

- A. Acute adrenal gland insufficiency
- B. Acute gastritis
- C. Acute enterocolitis
- D. Collapse
- E. Diabetes mellitus

142. After a contact with chemicals a plant worker has suddenly developed stridor, voice hoarseness, barking cough, progressing dyspnea. Objective examination reveals acrocyanosis. What is your provisional diagnosis?

- A. Laryngeal edema
- B. Laryngeal carcinoma
- C. PATE
- D. Pulmonary atelectasis
- E. Pneumothorax

143. A 58-year-old patient complains of general weakness, weight loss up to 10 kg within the last 1,5 months, progressive pain in the small of the back, raise of blood pressure to 220/160 mm Hg, subfebrile body temperature. Objecti-

vely: tuberos slightly movable lump can be palpated in the right subcostal area; veins of spermatic cord and scrotum are dilated. Blood test: Hb - 86 g/l, ESR - 44 mm/h. Urine test: specific gravity - 1020, proteine - 0,99 g/l, erythrocytes - all field of vision, leukocytes - 4-6 in the field of vision. The provisional diagnosis is:

- A. Kidney tumor
- B. Urolithiasis
- C. Acute pyelonephritis
- D. Acute glomerulonephritis
- E. Nephroptosis

144. A 58-year-old patient complains of headache in the occipital region, nausea, choking, opplotentes. The presentations appeared after a physical exertion. Objectively: the patient is excited. Face is hyperemic. Skin is pale. Heart sounds are regular, the 2nd aortic sound is accentuated. BP - 240/120 mm Hg, heart rate - 92/min. Auscultation reveals some fine moist rales (crackles) in the lower parts of the lungs. Liver is not enlarged. ECG shows signs of hypertrophy and left ventricular overload. What is the most likely diagnosis?

- A. Complicated hypertensive crisis
- B. Acute myocardial infarction, pulmonary edema
- C. Bronchial asthma exacerbation
- D. Uncomplicated hypertensive crisis
- E. Community-acquired pneumonia

145. A 37-year-old patient complains of pain in the lumbar spine, which increases during walking, limited mobility, edema of the right side of abdomen. Focal tuberculosis is recorded in the anamnesis. X-ray shows destruction of adjacent surfaces of the bodies of the 1-2 lumbar vertebrae, vertebral bodies height is decreased, intervertebral fissure cannot be detected. Abdominal US reveals a growth 15x20 cm in size in the retroperitoneal space and echo signs of liquid. What diagnosis can be suspected?

- A. Lumbar tuberculous spondylitis
- B. Fracture of the 1-2 lumbar vertebrae body
- C. Metastatic damage of vertebral column
- D. Lumbar spondylolisthesis
- E. Osteochondrosis

146. A 45-year-old patient (14-year-long work record as a house painter) upon the contact with synthetic paint develops skin reddening, edema, severe itching and oozing lesions on her face. Symptoms disappear after the contact with this chemical substance stops but even the smell of paint alone is enough to make them reappear each time. Each recurrence is characterised by increased severity of symptoms. What provisional diagnosis can be made?

- A. Professional eczema
- B. Simple contact dermatitis
- C. Allergic contact dermatitis
- D. Urticaria
- E. Toxicodermia

147. In cold season a patient was delivered to a hospital. He was rescued from drowning in a body of water. There was no contact of his airways with water. The patient is anxious, pale, complains of pain and numbness of limbs, has cold shivering. Breathing rate is 22/min, BP is 120/90 mm Hg, heart rate is 110/min, rectal temperature is 34,5°C. What kind of warming should be prescribed to the patient?

- A. Passive warming
- B. Infusion of 37°C solutions
- C. Hot compresses
- D. Heat bath
- E. Hemodialysis with blood warming

148. Survey radiograph of a 52-year-old worker of an agglomeration plant (28 years of experience, the concentration of metal dust is 22-37 mg/m³) shows mildly pronounced interstitial fibrosis with diffused contrast well-defined small nodular shadows. The patient has no complaints. Pulmonary function is not compromised. What is the provisional diagnosis?

- A. Siderosis
- B. Silicosis
- C. Anthraco-silicatosi
- D. Silicatosi
- E. Anthracosis

149. A week before, a 65-year-old male patient suffered an acute myocardial infarction. His general condition has deteriorated: he complains of dyspnea at rest, pronounced weakness. Objectively: edema of the lower extremities, ascites is present. Heart borders are extended, paradoxical pulse is 2 cm displaced from the apex beat to the left. What is the most likely diagnosis?

- A. Acute cardiac aneurysm
- B. Recurrent myocardial infarction
- C. Acute pericarditis
- D. Cardiosclerotic aneurysm
- E. Pulmonary embolism

150. A 60-year-old patient complains of nearly permanent sensation of heaviness and fullness in the epigastrium, that increases after eating, foul-smelling eructation, occasional vomiting with food consumed 1-2 days ago, weight loss. 12 years ago he was first found to have an ulcer of pyloric channel. The patient has taken ranitidine for periodic hunger pain. The patient's condition has been deteriorating over the last 3 months. Objectively: splashing sound in the epigastrium is present. What kind of complication is it?

- A. Pyloric stenosis
- B. Penetration of gastric ulcer
- C. Functional pyloric spasm
- D. Foreign body in the stomach (bezoar)
- E. Malignization of gastric ulcer

151. A 5-year-old child has body temperature risen up to febrile numbers, suffers from inertness, weakness. Examination revealed hemorrhage on the skin of limbs and torso. Enlargement of cervical and axillary lymph nodes can be detected. The liver is 4 cm below the costal arch; the spleen is 6 cm below the costal arch. Blood test: erythrocytes - $2,3 \cdot 10^{12}/l$, Hb- 60 g/l, platelets - $40 \cdot 10^9/l$, leukocytes - $32,8 \cdot 10^9/l$, eosinophiles - 1%, band neutrophiles - 1%, segmented neutrophiles - 12%, lymphocytes - 46%, monocytes - 1%, blasts - 40%, Duke's bleeding time test result is 9 min. What examination is necessary to make the diagnosis?

- A. Myelogram
- B. Lymph nodes biopsy
- C. US of abdominal cavity
- D. Detection of hepatitis markers
- E. Investigation of platelets dynamic functions

152. A child from primipregnancy was born in a term labor and has body weight of 4000 g and body length of 57 cm. When born, he was nonresponsive to examination. Diagnosis is diffuse. Heart rate is 80/min. What resuscitation measures should be prescribed?

- A. Begin ALV with mask
- B. Introduce 100% oxygen
- C. Intubate and begin ALV
- D. Tactile stimulation
- E. Administer naloxone

153. A 20-year-old patient was delivered to a surgical unit complaining of an incised wound on his right forearm that has been bleeding for 1,5 days. Suffers from general weakness, vertigo, cold sweat, opplotentes. Skin and visible mucous membranes are pale. Heart rate is 110/min, BP is 100/70 mm Hg. Blood test: Hb is 100 g/l, erythrocytes $2,5 \cdot 10^{12}/l$. What is the cause for the patient's general condition?

- A. Posthemorrhagic anemia
- B. Aplastic anemia
- C. Wound infection
- D. Concomitant disease
- E. Acute thrombophlebitis

154. A 20-year-old parturient woman has the I labor stage. The pregnancy is full-term. Labors occur every 3 minutes and last for 55 seconds. Fetus presentation is polar, the head is pressed to the small pelvis entrance. Heart rate of the fetus is 150/min, distinct and rhythmic. Vagina examination: uterus cervix is smoothed out; mouth of the womb is 2 cm open; fetal bladder is intact; the head is presented over the I plane of small pelvis; moderate mucous-bloody discharge is observed. What phase of the I labor stage is it?

- A. Latent
- B. Active
- C. Slowing-down
- D. Physiological preliminary period
- E. Primary uterine inertia

155. A 23-year-old woman after stress has developed thirst, polydipsia, polyuria, weight loss, increasing fatigue. Later she developed nausea and somnolence, lost consciousness and was hospitalised. Glycemia is 27 mmol/l, acetone in urine is sharply positive. Treatment for ketoacidotic coma was initiated. When would it be advisable to start preventive treatment of hypoglycemia by introduction of 5% glucose solution?

- A. After glycemia rate drops to 13-14 mmol/l
- B. 2 hours after beginning of insulinotherapy
- C. When patient becomes conscious
- D. After glycemia rate becomes normal
- E. If glycemia decreases with the rate over 5 mmol/l per hour

156. A 53-year-old woman complains of weight loss up to 10 kg within the last 2 years, liquid foul-smelling stool two times a day that poorly washes off the toilet, periodic bouts of nausea, girdle pain in the upper abdomen. Objectively: pain in Gubergrits zone (on the right from navel) and Mayo-Robson's point. Biochemical blood analysis: glucose - 3,2 mmol/l, bilirubin - 16,5 micromole/l, crude protein - 56,4 g/l. Urine diastase - 426 g/h/l. D-xylose test (oral administration of 25 g of d-xylose) after 5 hours reveals 3 g of xylose in urine. The most likely diagnosis is:

- A. Pancreatitis. Malabsorption syndrome
- B. Pseudomembranous colitis
- C. Nonspecific ulcerative colitis
- D. Irritable bowel syndrome
- E. Chronic gastritis

157. A 23-year-old patient after intake of brake fluid has developed anuria that has been lasting for 5 days already. Creatinine level increased up to 0,769 mmol/l. What treatment tactics should be chosen in the given case?

- A. Hemodialysis
- B. Detoxification therapy
- C. Antidotal therapy
- D. Diuretics
- E. Plasmapheresis

158. A 15-year-old teenager has undergone medical examination in military recruitment center. The following was revealed: interval systolic murmur at the cardiac apex, accent of the II heart sound over the pulmonary artery, tachycardia. What additional examination method will be the most informative for determining diagnosis?

- A. Echocardiography
- B. Electrocardiography
- C. X-ray
- D. Phonocardiography
- E. Rheography

159. A 64-year-old patient has been hospitalised with complaints of progressive jaundice that developed over 3 weeks ago without pain syndrome, general weakness, loss of appetite. Objectively: temperature is 36,8°C, heart rate is 78/min, abdomen is soft and painless, peritoneum irritation symptoms are not detected, palpation reveals sharply enlarged tense gallbladder. What disease can be characterised with these symptoms?

- A. Cancer of pancreas head
- B. Duodenal ulcer
- C. Acute cholecystitis
- D. Chronic cholecystitis
- E. Cholecystitis caused by lamblia

160. A 22-year-old woman on a reduced diet, vegetarian, attended a hospital with complaints of distorted smell and taste perception and lesions in the angles of her mouth. Objectively: sclera is distinctly blue. Diagnosis: iron-deficiency anemia. What clinical syndrome is expressed primarily?

- A. Sideropenic
- B. Anemic
- C. Hemorrhagic
- D. Hemolytic
- E. Myelodysplastic

161. A 15-year-old patient complains of excessive body weight, headache, irritability, rapid fatigability. Significant increase of body weight occurred at the age of 14. Objectively: weight is 90 kg; height is 160 cm, proportional body built. Fatty tissue is distributed evenly. There are thin pink striae (stretch marks) on the thighs, abdomen and mammary glands. BP - 145/90 mm Hg. Provisional diagnosis is:

- A. Pubertate dyspituitarism
- B. Alimentary constitutive obesity
- C. Somatoform autonomic dysfunction
- D. Itsenko-Cushing's disease
- E. Cushing's syndrome

162. A 6-year-old girl attended a general practitioner with her mother. The child complains of burning pain and itching in her external genitalia. The girl was taking antibiotics the day before due to her suffering from acute bronchitis. On examination: external genitalia are swollen, hyperemic, there is white deposit accumulated in the folds. The most likely diagnosis is:

- A. Candidal vulvovaginitis
- B. Trichomoniasis
- C. Nonspecific vulvitis
- D. Helminthic invasion
- E. Herpes vulvitis

163. A 44-year-old man complains of dyspnea

with sensation of lack of air on inhale, palpitations occurring during slight physical exertion, and shin edemas that appear in evening and resolve in morning. His condition has been lasting for 5 months already, deterioration is gradual. What method of instrumental diagnostics allows to verify decrease of systolic function in this patient?

- A. Echocardiography
- B. Electrocardiography
- C. Computed tomogram
- D. Phonocardiography
- E. Holter blood pressure monitoring

164. When playing in a kindergarten a 3-year-old child suddenly developed dyspnea, paroxysmal compulsive dry cough. The face is cyanotic, the eyes are tearful. Vomiting occurred several times. Breathing is weakened over the whole right side of the chest. The provisional diagnosis is:

- A. Foreign body
- B. Obstructive bronchitis
- C. Bronchial asthma
- D. Hysteria fit
- E. Stenosing laryngotracheitis

165. A patient with otopyosis is in sharply deteriorating condition: he developed headache, vomiting, febrile temperature, general hyperesthesia. Meningeal symptoms and stagnant optic disks are observed. There is no focal symptoms. Liquor is turbid, blood pressure is high, albuminocytological dissociation occurs with neutrophils. What disease can be suspected?

- A. Secondary purulent meningitis
- B. Meningoencephalitis
- C. Serous meningitis
- D. Primary purulent meningitis
- E. Subarachnoid hemorrhage

166. A 25-year-old patient is not married and has sexual relations with several partners. During the last 3 months he noticed small amount of mucoserous secretions produced from urethra. Subjectively: periodical itching or burning pain in urethra. Two months ago pain in knee joint developed. Possibility of trauma or exposure to cold is denied by the patient. During the last week eye discomfort is noted - lacrimation and itching. What provisional diagnosis can be suggested?

- A. Reactive arthritis
- B. Rheumatoid arthritis
- C. Seasonal pollinosis
- D. Bacterial nonspecific urethral conjunctivitis
- E. URTI with conjunctiva and joints affected

167. A 19-year-old patient complains of severe pain in axillary crease. Condition onset was a week ago after her swimming in cold river and epilation. The next day painful "boil" appeared that was becoming larger every day and became a plum-sized tumor. Upon examination nodular conical growths joined together

are detected, the skin covering them is bluish-red in colour. Some nodules have fistulous openings producing thick purulent mass. Body temperature is $38,5^{\circ}\text{C}$, general malaise. The most likely diagnosis is:

- A. Hydradenitis
- B. Carbuncle
- C. Cutaneous tuberculosis
- D. Necrotizing ulcerative trichophytosis
- E. Pyoderma chancriformis

168. A patient complains of weight gain, chill, edemas, xeroderma, somnolence, difficulties with focusing. Objectively: height is 165 cm; weight is 90 kg; body proportions are of female type, t° - $35,8^{\circ}\text{C}$, heart rate - 58/min, BP - 105/60 mm Hg. Heart sounds are weakened, bradycardia is observed. Other internal organs have no changes. Thyroid gland cannot be palpated. Milk secretion from mammary glands is observed. Hormone investigation revealed increased levels of thyroid-stimulating hormone (TSH) and prolactin, and decreased level of thyroxine (T4). Which one is the cause for obesity?

- A. Primary hypothyroidism
- B. Secondary hypothyroidism
- C. Prolactinoma
- D. Hypopituitarism
- E. Adiposogenital dystrophy

169. A 54-year-old patient complains of weakness, jaundice, itching skin. Disease onset was 1,5 months ago: fever up to 39°C appeared at first, with progressive jaundice developed 2 weeks later. On hospitalisation jaundice was severely progressed. Liver cannot be palpated. Gallbladder is enlarged and painless. Blood bilirubin is 190 micromole/l (accounting for direct bilirubin). Stool is acholic. What is the most likely jaundice genesis in this patient?

- A. Mechanical jaundice
- B. Hepatocellular jaundice
- C. Hemolytic jaundice
- D. Caroli syndrome
- E. Gilbert's syndrome

170. A 22-year-old patient complains of 8-months-long delay of menstruation. Anamnesis: menarche since the age of 12,5. Since the age of 18 menstruations are irregular. No pregnancies. Mammary glands have normal development; when the nipples are pressed, milk drops are discharged. On gynecological examination: moderate uterus hypoplasia. On hormonal examination: prolactin level exceeds the norm two times. On computed tomogram of the sellar region: a space-occupying lesion 4 mm in diameter is detected. The most likely diagnosis is:

- A. Pituitary tumor
- B. Lactation amenorrhea
- C. Stein–Leventhal syndrome (Polycystic ovary syndrome)
- D. Sheehan's syndrome
- E. Cushing's disease

171. A 2-year-old child in a satisfactory condition periodically presents with moderate proteinuria, microhematuria. US results: the left kidney is undetectable, the right one is enlarged, there are signs of double pyelocaliceal system. What investigation is required to specify the diagnosis?

- A. Excretory urography
- B. Micturating cystography
- C. Retrograde urography
- D. Doppler study of renal vessels
- E. Radioisotope renal scan

172. For the last 3 years a 12-year-old boy has been suffering from stomachache, abdominal distension, nausea, periodical liquid fatty stool, grey in color, with rotten smell. On palpation: pain in the epigastrium, Desjardins' pancreatic point and Chauffard's triangle; positive Mayo-Robson's sign. Insufficiency of pancreas exocrine function is suspected. What method is the most informative for pancreas exocrine function assessment?

- A. Detection of elastase-1 in feces
- B. Determining tripsin content in blood serum
- C. Pancreas echography
- D. Determining amylase content in blood and urine
- E. Scatological test

173. A 34-year-old patient was delivered to a first-aid center with open fracture of the lower leg bones. Upon examination bleeding is stated: blood flows in pulsating bursts. What actions should be taken at this stage of medical aid?

- A. Apply tourniquet to the thigh proximally to the place of hemorrhage and deliver the patient to operating room
- B. Provide immobilization and deliver the patient to a hospital
- C. Apply tourniquet to the thigh distally to the place of hemorrhage and deliver the patient to operating room
- D. Apply pressure dressing to stop hemorrhage and deliver the patient to operating room
- E. Deliver the patient to operating room

174. A 26-year-old patient with affective bipolar disorder has developed a condition manifested by mood improvement, behavioural and sexual hyperactivity, verbosity, active body language, reduced need for sleep. Which of the following drugs are most effective in this case?

- A. Neuroleptics with a sedative effect
- B. Antidepressants with an activating effect
- C. Neuroleptics with an activating effect
- D. Tranquilizers
- E. Antidepressants with a sedative effect

175. An emergency doctor has diagnosed a 32-year-old woman with generalized convulsive status epilepticus. The deterioration in the patient's condition is caused by a sudden gap in the epilepsy treatment. Specify the doctor's further tactics:

- A. Hospitalization in the intensive care unit
- B. Hospitalization in the department of neurology
- C. Hospitalization in the department of neurosurgery
- D. Outpatient monitoring by a neuropathologist
- E. Outpatient monitoring by a neurosurgeon

176. A 19-year-old patient complains of dyspnea during physical exertion. He often has bronchitis and pneumonia. Cardiac murmur has been observed since his childhood. On auscultation: there is splitting of II heart sound over pulmonary arteria, systolic murmur in the third intercostal space near the left sternum margin. ECG test shows right bundle-branch block. What is the provisional diagnosis?

- A. Interatrial septum defect
- B. Open arterial duct
- C. Coarctation of aorta
- D. Aortic stenosis
- E. Mitral valve insufficiency

177. A 30-year-old patient was in a car accident. He is unconscious, pale, has thready pulse. In the middle third of the right thigh there is an extensive laceration with ongoing profuse external arterial bleeding. What urgent actions must be taken to save the life of the patient?

- A. Tourniquet above the wound of the right thigh
- B. Tourniquet below the wound of the right thigh
- C. Artificial lung ventilation
- D. Precordial thump
- E. Plaster bar

178. A 75-year-old male patient complains of slight pain in the right iliac region. The abdominal pain arose 6 days ago and was accompanied by nausea. Surgical examination revealed moist tongue, heart rate - 76 bpm. BP - 130/80 mm Hg. Abdomen is soft, slightly painful in the right iliac region on deep palpation, the symptoms of the peritoneum irritation are doubtful. In blood: RBCs - $4,0 \cdot 10^{12}/l$, Hb - 135 g/l, WBCs - $9,5 \cdot 10^9/l$, stab neutrophils - 5%, segmentonuclear - 52%, lymphocytes - 38%, monocytes - 5%, ESR - 20 mm/h. Specify the doctor's further tactics:

- A. Emergency operation for acute appendicitis
- B. Hospitalization, dynamic surveillance
- C. Send the patient home
- D. Refer the patient to a district therapist
- E. Administration of additional examination: abdominal ultrasound, x-ray contrast study of the gastrointestinal tract

179. On the 10th day postpartum a puerperant woman complains of pain and heaviness in

the left mammary gland. Body temperature is 38, 8°C, Ps- 94 bpm. The left mammary gland is edematous, the supero-external quadrant of skin is hyperemic. Fluctuation symptom is absent. The nipples discharge drops of milk when pressed. What is a doctor's further tactics?

- A. Antibiotic therapy, immobilization and expression of breast milk
- B. Compress to both mammary glands
- C. Inhibition of lactation
- D. Physiotherapy
- E. Opening of the abscess and drainage of the mammary gland

180. An 8-year-old child was hospitalized for fever up to 39, 8°C, inertness, moderate headache, vomiting. Examination revealed meningeal symptoms. Lumbar puncture was performed. The obtained fluid had raised opening pressure, it was transparent, with the cell count of 450 cells per 1 mL (mainly lymphocytes - 90%), glucose level of 2,6 mmol/l. What causative agent might have caused the disease in the child?

- A. Enterovirus
- B. Meningococcus
- C. Koch's bacillus
- D. Staphylococcus
- E. Pneumococcus

181. A 25-year-old patient during self-examination detected a tumor in the upper external quadrant of the right mammary gland. On palpation: painless, dense, mobile growth 2 cm in diameter is detected in the mammary gland; no changes in the peripheral lymph nodes are observed. On mammary glands US: in the upper external quadrant of the right mammary gland there is a space-occupying lesion of increased echogenicity 21x18 mm in size. The most likely diagnosis is:

- A. Fibrous adenoma
- B. Lacteal cyst
- C. Diffuse mastopathy
- D. Breast cancer
- E. Mastitis

182. A 20-year-old woman complains of feeling of air shortage, lingering dull pain in the heart area, irritability. Objectively: general condition is satisfactory, heart rate lability, BP is 130/60 mm Hg. ECG reveals disruption of repolarization processes. The patient is diagnosed with somatoform autonomic dysfunction of cardiac type. Specify the conditions of the patient treatment:

- A. Out-patient treatment
- B. In-patient treatment in therapeutics department
- C. In-patient treatment in cardiology department
- D. In-patient treatment in cardiac surgery department
- E. In-patient treatment in psychiatric department

183. A 70-year-old patient consulted a doctor about arrhythmic cardiac activity, dyspnea. Objectively: BP - 150/90 mm Hg, extrasystole arrhythmia (10-12 beats per minute), left ventricular systolic dysfunction (ejection fraction at the rate of 42%). Which of anti-arrhythmic drugs should be administered as initial therapy in this case?

- A. Amiodarone
- B. Flecainide
- C. Encainide
- D. Moracizine
- E. Digoxin

184. A 45-year-old male patient complains of acute pain in his right side irradiating to the right thigh and crotch. The patient claims also to have frequent urination with urine which resembles a "meat slops" in color. The patient has no previous history of this condition. There is costovertebral angle tenderness on the right (positive Pasternatsky's symptom). What is the most likely diagnosis?

- A. Urolithiasis
- B. Acute appendicitis
- C. Acute pyelonephritis
- D. Acute cholecystitis. Renal colic
- E. Acute pancreatitis

185. A 38-year-old man works within the range of ionizing radiation. At a routine medical examination he presents no problems. In blood: RBCs - $4,5 \cdot 10^{12}/l$, Hb- 80 g/l, WBCs - $2,8 \cdot 10^9/l$, thrombocytes - $30 \cdot 10^9/l$. Decide if this person can work with sources of ionizing radiation:

- A. Working with radioactive substances and other sources of ionizing radiation is contraindicated
- B. The patient is allowed to work with radioactive substances
- C. The patient can only work with radioactive substances of low activity
- D. The patient can be allowed to work after an extended medical examination
- E. The patient is allowed to work with radioactive substances for the limited period of time

186. A maternity patient breastfeeding for 1,5 weeks has attended a doctor. She considers the onset of her disease to be when proportional breast engorgement occurred. Mammary glands are painful. Body temperature is 36, 6°C. Expression of breast milk is hindered. The most likely diagnosis is:

- A. Lactostasis
- B. Infiltrative mastitis
- C. Suppurative mastitis
- D. Chronic cystic mastitis
- E. Gangrenous mastitis

187. A 12-year-old girl complains of general weakness, rise of body temperature up to 38, 2°C, pain and swelling of knee joints, feeling of cardiac rhythm disruption. The chi-

ld had tonsillitis 3 weeks ago. The knee joints are swollen, local raise of temperature is observed, mobility is reduced. Heart sounds are weakened, extrasystole is present; at the cardiac apex systolic noise can be auscultated, which is not conducted to the left axillary region. ESR is 38 mm/h. CRP 2+. Antistreptolysin-O titers are 400. The most likely disease is:

- A. Acute rheumatic fever
- B. Somatoform autonomic dysfunction
- C. Non-rheumatic carditis
- D. Juvenile rheumatoid arthritis
- E. Reactive arthritis

188. A 60-year-old man has a diet consisting of unvaried food staples: mostly cereals, potato, pasta; few vegetables and little fats (especially animal fats). During medical examination he complains of deterioration of his twilight vision. This condition can be caused by lack of:

- A. Retinol
- B. Amino acids
- C. Fats
- D. Calcium
- E. Carbohydrates

189. A 45-year-old patient was hospitalised in surgical in-patient unit with intermuscular phlegmon of the right thigh on the 6th day from the onset of disease. Abscess formed under the fascia lata was diagnosed, lanced and widely drained, necrotic tissues were removed. Antibiotic therapy with cephalosporines and the III generation fluoroquinolones was prescribed, as well as immune corrective and detoxification infusion therapy (2,5 liters per day), diuresis stimulation, UV irradiation of blood and plasmapheresis. What is the main component of sepsis prevention?

- A. Surgical invasion
- B. General antibiotic therapy
- C. Topical antibiotic therapy
- D. Immune correction therapy
- E. Detoxification therapy

190. An Rh-negative woman with 32-week-long term of pregnancy has been examined. It was observed that Rh-antibodies titer had increased four times within the last 2 weeks and was 1:64. First two pregnancies ended in antenatal death of fetus caused by hemolytic disease. What tactics of pregnancy management should be chosen?

- A. Preterm delivery
- B. Delivery at 37 weeks term
- C. Rh-antibody test in 2 weeks; if Rh-antibodies increase in number conduct delivery
- D. Introduction of anti-Rh immunoglobulin
- E. US examination to determine signs of fetal erythroblastosis

191. A 2-year-old child has been suffering since birth from recurring inflammatory diseases of lungs, purulent pansinusites, hearing deterioration, multiple cylindrical bronchiectases. Dextrocardia is observed. On biopsy:

ultrastructural change of ciliated epithelium. What is the basis of the given syndrome?

- A. Primary ciliary dyskinesia
- B. Proteoglycans insufficiency
- C. Surfactant deficit
- D. Muscle cells atony
- E. Alpha-1-antitrypsin deficiency

192. A newborn infant (the first labor, lasted for 26 hours) is 1-day-old, postmature; body weight is 3850 g; body length is 52 cm. Delivery was performed by applying obstetrical forceps in sincipital presentation, Apgar score is 1/3. The face is bluish-pale. The head is thrown back; severe birth trauma is present; the infant is excitable, shrill "cerebral scream" is present; the eyes are half-open; facial expression is attentive; hyperesthesia, hypersthenia and readiness for convulsions are present. Liquor has high content of erythrocytes, lymphocytic cytosus occurs. The most likely diagnosis is:

- A. Subarachnoid hemorrhage
- B. Epidural hemorrhage
- C. Subdural hemorrhage
- D. Intraventricular hemorrhage
- E. Intracerebral hemorrhage

193. A 74-year-old patient visited a urologist with complaints of pain above the pubis and inability to urinate for 8 hours. At home he had taken antispasmodics and had a warm bath but no improvement occurred. Objectively: abdomen is soft and painful above the pubis; dullness of percussion sound is observed above the pubis. Murphy's (Pasternatski's) punch sign is negative on the both sides. What condition does the patient have?

- A. Acute urinary retention
- B. Paradoxal ischuria
- C. Shronic urinary retention
- D. Anuria
- E. Oliguria

194. A 37-year-old patient has been undergoing treatment of diskogenic lumbosacral radiculitis for a month. There is skin numbness observed at the lateral surface of the right lower extremity. Achilles jerk is absent. MRI of lumbar spine revealed intervertebral disk L_5-S_1 prolapse up to 8 mm. Choose the further tactics for patient treatment:

- A. Surgical extraction of intervertebral disk
- B. Conservative treatment
- C. Stabilizing spinal surgery
- D. Corset
- E. Manual therapy

195. A 40-year-old patient complains of constant moderate pain in the lumbar spine and significantly reduced mobility. The patient has been suffering from this condition for the last 7 years since pain appeared first in the sacrum area. X-ray: ankylosis of sacroiliac articulation, significant narrowing of intervertebral joint fissures of lumbar vertebrae and calcification of spinal ligaments. What pathology is

most likely to cause such X-ray image?

- A. Ankylosing spondylitis
- B. Spinal tuberculosis
- C. Spinal osteochondrosis
- D. Vertebral osteochondropathy
- E. Rheumatoid arthritis

196. A 7-year-old child became ill again 2 weeks after he had tonsillitis. There are the following complaints: temperature rise up to 38°C , hemorrhagic rash on the extremities, enlargement of the ankle joints. Blood test: hemoglobin is 120 g/l, platelets are $170 \cdot 10^9/l$, ESR is 30 mm/h. Urine test: proteinuria up to 0,7 g/l, cylinders - 5-6 in the field of vision, erythrocytes - 8-10 in the field of vision. What mechanism of hemorrhagic syndrome is present in the given case?

- A. Vessel wall damage caused by immune complexes
- B. Platelet dysfunction
- C. Suppression of hematopoietic stem cells
- D. Decrease of adhesive-aggregative function of platelets
- E. Vessel wall damage caused by bacteria

197. A 48-year-old patient was delivered to a hospital in-patient unit with uterine bleeding that occurred after the 2-week-long delay of menstruation. Anamnesis states single birth. Examination of the uterine cervix with mirrors revealed no pathologies. On bimanual examination: uterus is of normal size, painless, mobile; uterine appendages have no changes. Discharge is bloody and copious. What primary hemostatic measure should be taken in the given case?

- A. Fractional curettage of uterine cavity
- B. Hormonal hemostasis
- C. Hemostatics
- D. Uterine tamponade
- E. Uterotonics

198. A 30-year-old woman complains of irregular copious painful menstruations, pain irradiates to the rectum. Anamnesis states 10-year-long infertility. On bimanual examination: uterus is of normal size; uterine appendages on the both sides are corded, with restricted mobility, painful; there are dense nodular painful growths detected in the posterior fornix. A doctor suspects endometriosis. What method allows to verify this diagnosis?

- A. Laparoscopy
- B. Diagnostic curettage of uterine cavity
- C. Paracentesis of posterior fornix
- D. Uterine probing
- E. Hysteroscopy

199. A 14-year-old girl complains of tooth caries; the tooth should be filled. Anamnesis states that artificial mitral valve was installed 2 years ago due to mitral insufficiency. What anti-bacterial drug should be prescribed to prevent infective endocarditis?

- A. Amoxicillin
- B. Lincomycin
- C. Ceftriaxone
- D. Erythromycin
- E. Midecamycin

200. A 30-year-old woman complains of infertility during her 10-year-long married life. Menstruations occur since she was 14 and are irregular, with delays up to a month and longer. Body mass is excessive. Hirsutism is observed. On bimanual examination: uterine body is decreased in size; ovaries are increased in size, dense, painless, and mobile. The most likely diagnosis is:

- A. Stein–Leventhal syndrome (Polycystic ovary syndrome)
- B. Follicular cyst of ovaries
- C. Genital endometriosis
- D. Genital tuberculosis
- E. Inflammatory tumor of ovaries

INSTRUCTIONAL BOOK

Testing Board

TEST ITEMS FOR LICENSING EXAMINATION: KROK 2. MEDICINE.

Kyiv. Testing Board.
(English language).

Approved to print 13.03/№63/2. Paper size 60x84 1/8
Offset paper. Typeface. Times New Roman Cyr. Offset print.
Conditional print pages 24. Accounting publishing pages 28.
Issue. 1251 copies

List of abbreviations

A/G	Albumin/globulin ratio
A-ANON	Alcoholics anonymous
ACT	Abdominal computed tomography
ALT	Alanin aminotransferase
AP	Arterial (blood) pressure
AST	Aspartat aminotransferase
BP	Blood (arterial) pressure
BR	Breathing rate
bpm	Beats per minute
C.I.	Color Index
CBC	Complete blood count
CHF	Chronic heart failure
CT	Computer tomography
DIC	Disseminated intravascular coagulation
DCC	Doctoral controlling committee
DM-2	Non-Insulin dependent diabetes mellitus
DTP	Anti diphtheria-tetanus vaccine
ECG	Electrocardiogram
ESR	Erythrocyte sedimentation rate
FC	Function class
FEGDS	Fibro-esphago-gastro-duodenoscopy
Gy	Gray
GIT	Gastrointestinal tract
Hb	Hemoglobin
HbA1c	Glycosylated hemoglobin
Hct, Ht	Hematocrit
HDL	High-density lipoproteins
HR	Heart rate
IDDM	Insulin dependent diabetes mellitus
IHD	Ischemic heart disease
IU	International unit
MSEC	Medical and sanitary expert committee
NIDDM	Non-Insulin dependent diabetes mellitus
pCO ₂	CO ₂ partial pressure
pO ₂	O ₂ partial pressure
Pm	Per minute
Ps	Pulse rate
R	Roentgen
RBC	Red blood count
Rh	Rhesus
RR	Respiratory rate
S1 (S ₁)	Heart sound 1
S2 (S ₂)	Heart sound 2
TU	Tuberculin unit
U	Unit
USI	Ultrasound investigation
V/f	Vision field
WBC	White blood count
X-ray	Roentgenogram